Extended Lung Ultrasound to Differentiate Between Pneumonia and Atelectasis in Critically Ill Patients: A Diagnostic Accuracy Study

Mark E. Haaksma, MD[1–3]
Jasper M. Smit, MD[1–3]
Micah L. A. Heldeweg, MD[1–3]
Jip S. Nooitgedacht, BSc[1]
Harm J. de Grooth, MD, PhD[1,2]
Annemijn H. Jonkman, MSc[1,3]
Armand R. J. Girbes, MD, PhD[1,3]
Leo Heunks, MD, PhD[1,3]
Pieter R. Tuinman, MD, PhD[1–3]

OBJECTIVES: To determine the diagnostic accuracy of extended lung ultrasonographic assessment, including evaluation of dynamic air bronchograms and color Doppler imaging to differentiate pneumonia and atelectasis in patients with consolidation on chest radiograph. Compare this approach to the Simplified Clinical Pulmonary Infection Score, Lung Ultrasound Clinical Pulmonary Infection Score, and the Bedside Lung Ultrasound in Emergency protocol.

DESIGN: Prospective diagnostic accuracy study.

SETTING: Adult ICU applying selective digestive decontamination.

PATIENTS: Adult patients that underwent a chest radiograph for any indication at any time during admission. Patients with acute respiratory distress syndrome, coronavirus disease 2019, severe thoracic trauma, and infectious isolation measures were excluded.

INTERVENTIONS: None.

MEASUREMENTS AND MAIN RESULTS: Lung ultrasound was performed within 24 hours of chest radiograph. Consolidated tissue was assessed for presence of dynamic air bronchograms and with color Doppler imaging for presence of flow. Clinical data were recorded after ultrasonographic assessment. The primary outcome was diagnostic accuracy of dynamic air bronchogram and color Doppler imaging alone and within a decision tree to differentiate pneumonia from atelectasis. Of 120 patients included, 51 (42.5%) were diagnosed with pneumonia. The dynamic air bronchogram had a 45% (95% CI, 31–60%) sensitivity and 99% (95% CI, 92–100%) specificity. Color Doppler imaging had a 90% (95% CI, 79–97%) sensitivity and 68% (95% CI, 56–79%) specificity. The combined decision tree had an 86% (95% CI, 74–94%) sensitivity and an 86% (95% CI, 75–93%) specificity. The Bedside Lung Ultrasound in Emergency protocol had a 100% (95% CI, 93–100%) sensitivity and 0% (95% CI, 0–5%) specificity, while the Simplified Clinical Pulmonary Infection Score and Lung Ultrasound Clinical Pulmonary Infection Score had a 41% (95% CI, 28–56%) sensitivity, 84% (95% CI, 73–92%) specificity and 68% (95% CI, 54–81%) sensitivity, 81% (95% CI, 70–90%) specificity, respectively.

CONCLUSIONS: In critically ill patients with pulmonary consolidation on chest radiograph, an extended lung ultrasound protocol is an accurate and directly bedside available tool to differentiate pneumonia from atelectasis. It outperforms standard lung ultrasound and clinical scores.

KEY WORDS: air bronchogram; atelectasis; color Doppler; lung; pneumonia; ultrasound

Diffuse and local consolidations are common findings on chest radiographs (CXRs) performed in the ICU, which can be attributed to the high prevalence of (ventilator-associated) pneumonia and atelectasis in these patients (1, 2). Distinguishing the underlying cause for these infiltrates,

Copyright © 2022 by the Society of Critical Care Medicine and Wolters Kluwer Health, Inc. All Rights Reserved.

DOI: 10.1097/CCM.0000000000005303

Copyright © 2022 by the Society of Critical Care Medicine and Wolters Kluwer Health, Inc. All Rights Reserved.

that is, differentiating pneumonia from atelectasis, has critical treatment implications as pneumonia is associated with increased length of stay and mortality (3). A rapid and accurate diagnosis is thus essential but is often limited by low reliability of physical examination and CXR, the time required to demonstrate bacterial growth in cultures, and the lack of availability of additional diagnostic tools such as CT (4, 5). While lung ultrasound has established itself as an important bedside imaging alternative in this regard that clearly outperforms CXR, current diagnostic protocols were not developed for a population with high prevalence of basal consolidation of varying etiology (5–8).

Therefore, the diagnostic benefit of additional ultrasonographic measurements such as the evaluation of dynamic air bronchograms and pulsatile flow on color Doppler imaging have been investigated. The former has been shown to be highly specific for pneumonia, while the latter has been shown to be highly sensitive (9, 10). As follows, subsequent studies evaluated their diagnostic value singularly or as part of scoring systems such as the Clinical Pulmonary Infection Score (9, 11–15). While results of these studies seem promising, the evidence limits itself to relatively small and highly selected patient groups. Furthermore, no studies have evaluated whether the combined evaluation of multiple ultrasound patterns improves diagnostic performance for distinguishing pneumonia from atelectasis.

The current study aims to determine the diagnostic accuracy of the dynamic air bronchogram and color Doppler imaging for diagnosing pneumonia in patients with radiographic signs of pulmonary infiltrate(s). Diagnostic accuracy was evaluated for both ultrasound measurements separately, within a combined ultrasound approach, and in comparison to existing clinical protocols and scores.

MATERIALS AND METHODS

This prospective, diagnostic accuracy study was conducted in a mixed medical and surgical academic ICU (Amsterdam UMC, location VUmc, The Netherlands) using selective digestive decontamination. The protocol was approved by the local ethics board and registered in the Dutch trial registry (Registration identification: NL9186). Written informed consent was obtained from all patients or their next of kin. Patients were followed up 72 hours after ultrasound measurement were performed until gram-stain coloring and cultures were available to establish a diagnosis (see *Reference Test* below). STAndards for Reporting Diagnostic accuracy studies guidelines were followed (**Electronical Supplementary File 1**, http://links.lww.com/CCM/G743).

Patients

The study population consisted of adult (> 18 yr) patients admitted to the ICU. Patients were eligible for inclusion if CXR was performed and any consolidation was seen by the clinical team. Patients could only be included once. There was no selection for receiving mechanical ventilation. Exclusion criteria were acute respiratory distress syndrome (ARDS), coronavirus disease 2019 (COVID-19), severe thoracic injury due to trauma, or contact isolation. Patients were enrolled on weekdays based on the availability of scientific personnel and is presented as flowchart in the **Electronical Supplementary File 2** (http://links.lww.com/CCM/G744).

The ultrasound examination was performed within 24 hours of the CXR. Sex, age, reason for ICU admission, Sequential Organ Failure Assessment score, use of mechanical ventilation, ventilator settings, and inflammatory markers were obtained from the electronic patient directly after completion of the ultrasound examination. In nonventilated patients, FIO_2 was calculated based on the oxygen support modality. For nasal prongs and face masks, this was calculated as a 4% increase per liter of oxygen per minute supplied, starting at a base value of 24% at 1 L/min. For high-flow nasal oxygen therapy, the exact percentage was used in accordance with the setting. No other modalities (e.g., nonrebreather mask) were used.

Reference Test

The reference test was a composite reference standard. It was established through consensus of the clinical diagnosis of the treating physician (all > 10 yr of clinical experience) and of an independent researcher (also working as ICU physician). Both were blinded for the diagnosis of the other and for ultrasound measurements. In case of agreement, the diagnosis was established. In case of disagreement, a third independent researcher (also working as ICU physician) would have been asked to resolve the tie, which was however never needed. Both the treating physician and independent researcher had access to the full patient chart, which provided information on vital signs (e.g., temperature,

Copyright © 2022 by the Society of Critical Care Medicine and Wolters Kluwer Health, Inc. All Rights Reserved.

respiratory rate, pulse, blood pressure) and laboratory findings (e.g., WBC count, C-reactive protein level, Gram staining and cultures, tracheal secretions, and CXR). Only the treating physician participated in daily rounds with the other intensivists, the microbiology and radiology department, which provided updates and advice on infectious diseases, concomitant treatment, and results of imaging.

As we assumed that atelectasis and pneumonia could coexist, patients were classified as having pneumonia if both diagnoses were established, given the important treatment considerations for pneumonia.

Index Test

The index test was the diagnosis established directly at the bedside by the researcher performing ultrasound measurements. This researcher was blinded to all clinical data in the electronic patient health record and the reference test but aware of the consolidation seen on CXR and bedside available information on monitors, as this could not be blinded. The ultrasound-based diagnosis was derived using the following methods (for details on measurements, see *Image Acquisition* below):

1) Air bronchogram: A dynamic air bronchogram was considered to indicate pneumonia, whereas patients with a static air bronchogram were identified as having atelectasis.
2) Color Doppler imaging: If pulsatile flow was present, the patient was denoted as having pneumonia. If pulsatile flow was absent, the patient was identified as having atelectasis.
3) Combined approach: A three-step hierarchical decision tree was used as described in **Figure 1**.

First, the air bronchograms were evaluated. If it was deemed dynamic, the patient was classified as having pneumonia. Evaluation of the air bronchogram was prioritized over color Doppler imaging given its previously reported high specificity (9).

Second, in a patient with a static air bronchogram, color Doppler imaging was evaluated. If pulsatile flow was absent, pneumonia was ruled out and the patient was denoted as having atelectasis, given its previously reported high sensitivity (13, 14).

Third, if yet no ultrasound-based classification was established (i.e., static air bronchogram and present pulsatile flow), clinical data necessary to calculate the Lung Ultrasound Clinical Pulmonary Infection Score (lusCPIS) was provided after completion of the ultrasound examination. If this score was greater than 4, the patient was classified as having pneumonia and otherwise as having atelectasis.

4 Bedside Lung Ultrasound in Emergency (BLUE) protocol, Simplified Clinical Pulmonary Infection Score (sCPIS), and lusCPIS: the diagnosis was established as proposed in the original articles (8, 14, 16).

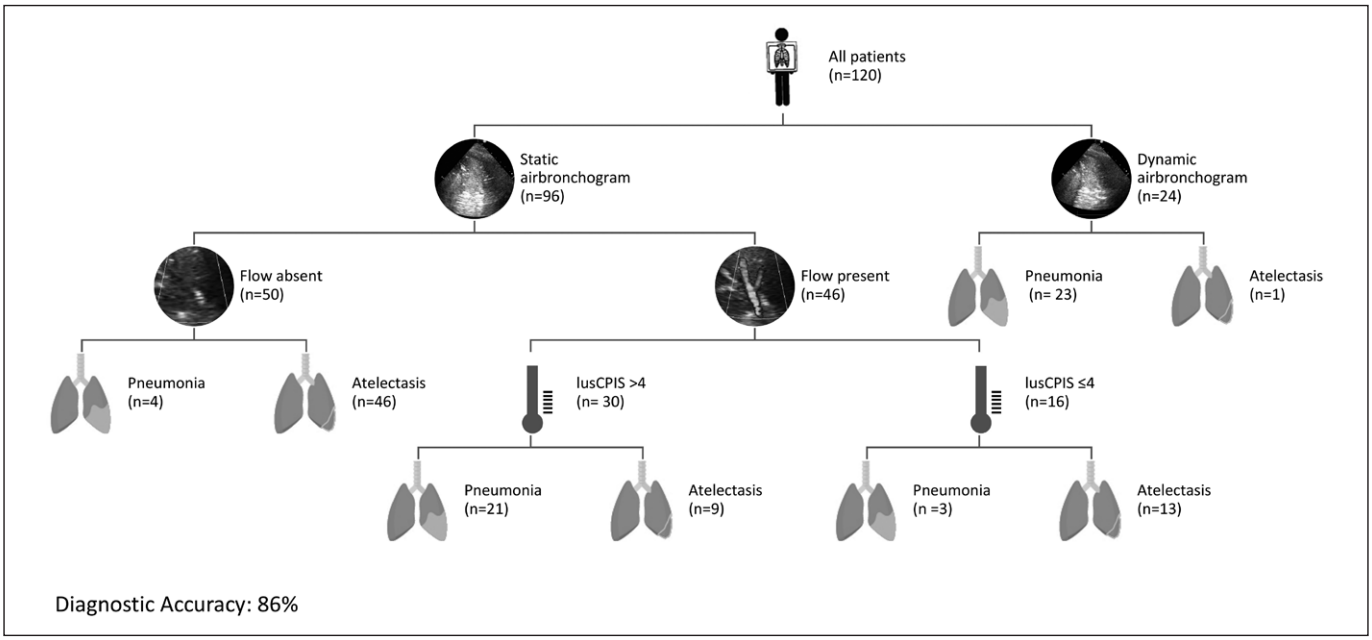

Figure 1. Population distribution according to decision tree. lusCPIS = Lung Ultrasound Clinical Pulmonary Infection Score.

Copyright © 2022 by the Society of Critical Care Medicine and Wolters Kluwer Health, Inc. All Rights Reserved.

Image Acquisition

Ultrasound measurements were performed by five independent researchers, four researchers with extensive ultrasound experience (> 2 yr of regular ultrasound use [M.E.H., J.M.S., M.L.A.H., P.R.T.]), and one researcher with basic experience (> 40 supervised exams [J.S.N.]). All images were obtained with a Philips CX50 ultrasound machine (Koninklijke Philips N.V., Amsterdam, The Netherlands). Measurements were performed following the BLUE protocol, with additional measurements in the Postero Lateral Alveolar and Pleural Syndrome (PLAPS) point (see *below*). Anterior BLUE points were acquired with a 2–5 MHz abdominal or 1–5 MHz cardiac transducer. Tissue harmonic imaging was disabled, in line with the manufacturer's suggestion for lung ultrasound. Image depth was set at 16 cm. For the PLAPS point, a 1–5 MHz cardiac transducer was used and image depth was freely adjustable by the operator to obtain the highest image quality.

Air bronchograms were assessed in B-mode with ultrasound settings to the researcher's preference. They were identified as small punctiform or linear hyperechoic artifacts within the consolidated tissue. If motion was visible in line with the patient's respiratory cycle (i.e., hyperechogenic spot moving to the distal lung fields upon inspiration, see **Fig. 2**), it was classified as dynamic.

Pulmonary vascular flow was assessed with color Doppler imaging. In order to maximize the sensitivity for low-velocity flow, the velocity scale was set to 0.25 m/s (10). To avoid interference of adjacent structures, the window for color Doppler assessment was minimalized. Flow was deemed present if pulsatile tree-like, tortuous or homogeneously distributed fragmented vascular structures were seen through several respiratory cycles in any part of the consolidated tissue (Fig. 2).

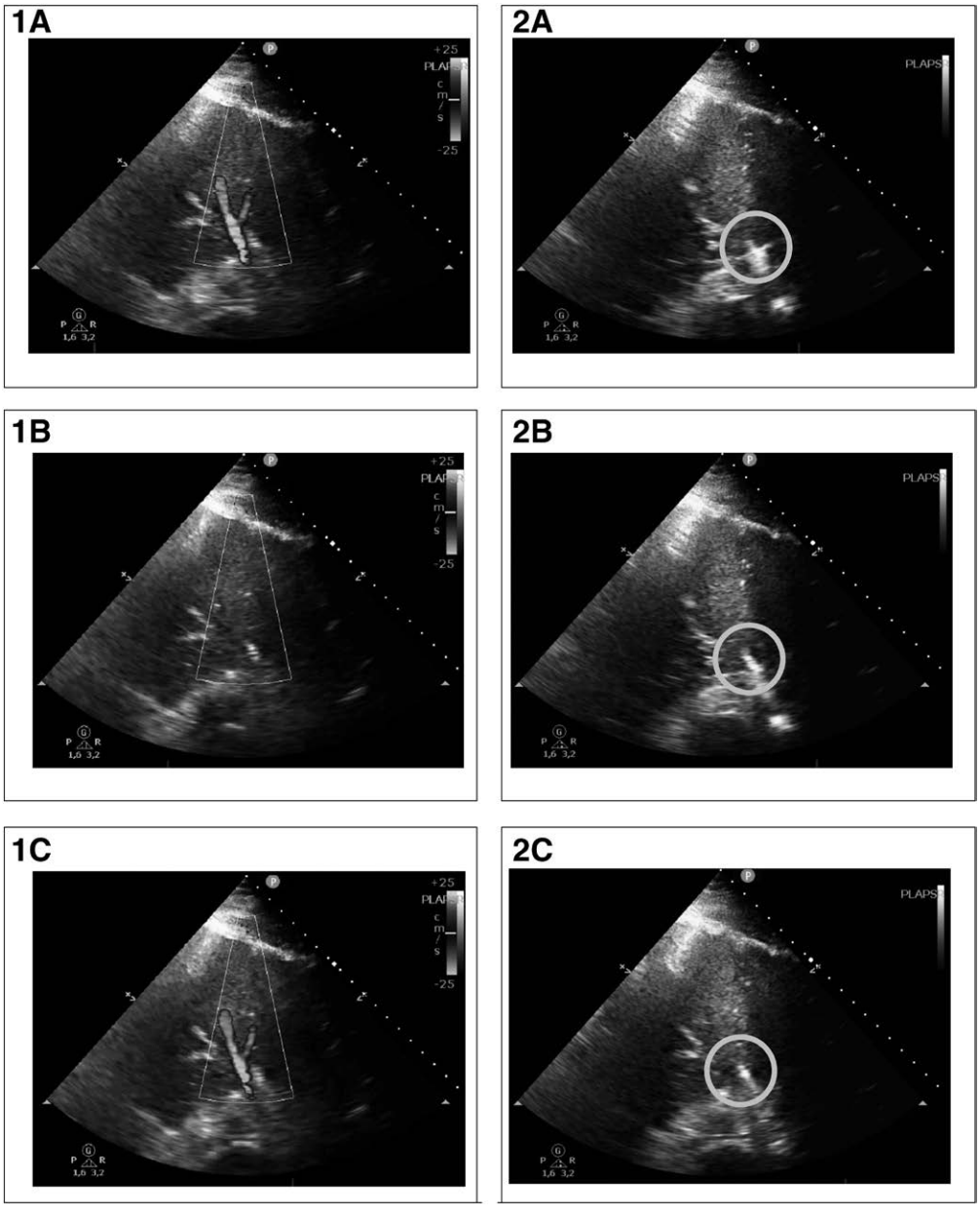

Figure 2. Dynamic air bronchogram and color Doppler imaging. 1**A**→1**B**→1**C**, Change of flow pattern according to heartbeat. 2**A**→**2B**→**2C**, Dynamic air bronchogram (hyperechogenic spot within *circle*) moving toward the more distal lung parts during inspiration. PLAPS = Postero Lateral Alveolar and Pleural Syndrome.

Copyright © 2022 by the Society of Critical Care Medicine and Wolters Kluwer Health, Inc. All Rights Reserved.

Reproducibility

For the reproducibility analysis of air bronchograms and color Doppler imaging, 20 de-identified clips were randomly chosen per category (i.e., 20 images for air bronchogram and 20 images for color Doppler imaging) upon completion of the study. All researchers participating in data acquisition were then asked to rate the clips independently and blinded to each other to evaluate the interrater reliability. For the intrarater reliability, the same set of images were reevaluated by all researchers in a shuffled order the next day.

Statistical Analysis

We aimed to find the sensitivity and specificity of the combined approach with a 10% margin of error. Assuming a prevalence of 40%, a sensitivity of 85%, and specificity of 80%, the required sample size was 118 (9, 11, 14, 17). Two additional subjects were included to account for potential data loss.

Baseline characteristics are presented for the entire cohort and per diagnosis (pneumonia vs atelectasis). These were tested for normality with the Shapiro-Wilk test, evaluation of histograms, and Q–Q plots and are presented as means ± SD, medians with interquartile range, or numbers (percentages) when appropriate. Differences in baseline characteristics between pneumonia and atelectasis as final diagnosis were tested with an independent samples *t* test, Mann-Whitney *U* test, or chi-square test when appropriate. The performance of diagnostic tests are presented as sensitivity, specificity, positive and negative predictive values, positive and negative likelihood ratios, and the diagnostic accuracy, all with a 95% CI (18). The diagnostic accuracy was calculated as the sum of true positive and true negative cases divided by all cases. Interrater and intrarater reliability for image assessment was assessed with Cohen's kappa. A p value of less than 0.05 was regarded as statistically significant. Statistical analyses were performed using SPSS IBM Version 22 (SPSS, Chicago, IL) and R Statistical Software Version 3.6 (R Foundation for Statistical Computing, Vienna, Austria).

RESULTS

The study was conducted during two separate intervals split by the first COVID-19 pandemic wave in our ICU (September 2018–January 2020 and September 2020–December 2020). Patient enrollment is summarized in the Electronical Supplementary File 2 (http://links.lww.com/CCM/G744).

Out of 128 patients that met enrollment criteria, 120 patients were included in the final analysis: ultrasound images could be acquired in 126 of 128 patients (98.4%), and six additional patients were excluded because of meeting ARDS diagnosis (n = 4) and withdrawal of consent (n = 2). Reasons for inability to obtain images were large dorsolateral surgical dressings in one patient and the absence of any basal consolidation in the other. In the final set of 120 patients, there were missing data for the calculation of the lusCPIS and sCPIS in nine patients (7.5%). For the lusCPIS in none of these cases, this would have impacted the interpretation of the score: in two patients, the score was already above the cutoff value for pneumonia, and in seven patients, the addition of the last missing parameter would not result in a score above the threshold. For the sCPIS, in two cases (1.6%), this could have potentially resulted in changing the diagnosis from atelectasis to pneumonia.

Of the 120 included patients, 51 (42.5%) were diagnosed with pneumonia as per reference test. Several differences in baseline characteristics were found between patients diagnosed with pneumonia and atelectasis, most notably inflammatory markers and vital signs (**Table 1**).

The presence of flow, static, and dynamic air bronchograms and the decision tree classification among patients diagnosed with pneumonia versus atelectasis is shown in **Table 2**. The resulting test characteristics are shown in **Table 3**.

The intrarater and interrater reliabilities ranged from substantial to excellent agreement. For evaluating air bronchograms intra rater kappa's ranged from 0.77 (95% CI, 0.47–1.00) to 1.00 (95% CI, not available [NA]) and for color Doppler imaging they ranged from 0.68 (0.35–1.00) to 1.00 (95% CI, NA). The interrater agreement was 0.86 (95% CI, 0.72–1.00) and 0.79 (95% CI, 0.65–0.92) for air bronchograms and color Doppler imaging, respectively. A detailed overview is provided in the **Electronical Supplementary File 3** (http://links.lww.com/CCM/G745).

Copyright © 2022 by the Society of Critical Care Medicine and Wolters Kluwer Health, Inc. All Rights Reserved.

TABLE 1.
Baseline Characteristics

Variable	Overall	Pneumonia	Atelectasis	*p*
Gender, male	82 (68.3)	39 (76.5)	43 (62.3)	0.115
Age, yr	69 (53–75)	64 (50–75)	70 (55–74)	0.363
Body mass index (kg/m^2)	25.2 (22.6–29.3)	24.7 (21.9–30.3)	25.9 (23.4–29.3)	0.569
Sequential Organ Failure Assessment	8 (6–11)	9 (6–11)	8 (6–11)	0.825
Reason for admission				
Neurologic	12 (10.1)	6 (12.0)	6 (8.7)	0.001
Pulmonary	39 (32.8)	30 (60.0)	9 (13.0)	
Cardiovascular	43 (35.8)	8 (16.0)	35 (50.7)	
Gastrointestinal	5 (4.2)	0 (0.0)	5 (7.2)	
Trauma	15 (12.5)	5 (10.0)	10 (14.5)	
Other	5 (4.2)	1 (2.0)	4 (5.8)	
Respiratory				
Ventilated	65 (54.2)	33 (64.7)	32 (46.4)	0.064
Respiratory rate	21 (17–25)	24 (18–27)	20 (16–22)	0.001
Pao_2/Fio_2 ratio	206 (145–283)	159 (120–217)	237 (165–335)	0.001
Inflammatory				
Temperature	37.0 (36.3–37.5)	37.2 (36.6–37.8)	36.8 (36.1–37.4)	0.007
WBC count	12.7 (8.9–16.5)	13.1 (8.9–16.6)	12.1 (8.9–16.0)	0.466
C-reactive protein	106 (44–221)	183 (85–302)	77 (34–177)	0.001
Positive culture	44 (38.3)	28 (57.1)	16 (24.2)	0.000
Tracheal secretion				
Absent or rare	70 (65.4)	22 (46.8)	48 (80.0)	
Abundant	18 (16.8)	13 (27.7)	5 (8.3)	0.001
Abundant and purulent	19 (17.8)	12 (25.5)	7 (11.7)	

Numbers are given as mean ± SD or median (interquartile range) or *n* (%).

DISCUSSION

The main findings of this study are that the dynamic air bronchogram has a high specificity, the presence of pulsatile flow on color Doppler imaging has a high sensitivity, and the extended lung ultrasound protocol (i.e., decision tree) yielded an overall high diagnostic accuracy for detecting pneumonia in a general ICU population with consolidation found on CXR. Additionally, other important findings are that the extended lung ultrasound protocol outperformed previously published protocols and that evaluation of dynamic air bronchograms and color Doppler imaging have good reliability. Therefore, our results both enrich and confirm previous literature, demonstrating that using extended lung ultrasound allows for accurate detection of pneumonia in ICU patients (9, 11, 13, 14).

While standard lung ultrasound has already shown to effectively diagnose pneumonia, it should be acknowledged that these studies bear some limitations. They were performed in a different setting, for example, emergency department, used overarching diagnostic categories such as alveolar consolidation including atelectasis and pneumonia as one finding, or used additional clinical parameters for differentiation (6–8). In the ICU, where a large proportion of patients is mechanically ventilated, often sedated and immobilized,

Copyright © 2022 by the Society of Critical Care Medicine and Wolters Kluwer Health, Inc. All Rights Reserved.

TABLE 2.
Contingency Table for Flow and Air Bronchogram

Diagnostic Modality	Number of Patients	Final Diagnosis		Total
		Pneumonia	Atelectasis	
Flow				
Present	*n*	46	22	68
Absent	*n*	5	47	52
Total	*n*	51	69	120
Air bronchogram				
Dynamic	*n*	23	1	24
Static	*n*	28	68	96
Total	*n*	51	69	120
Decision tree				
Pneumonia	*n*	44	10	54
Atelectasis	*n*	7	59	66
Total	*n*	51	69	120

basal consolidation is a very frequent phenomenon, hampering easy diagnosis, and creating the necessity for more elaborate examination (7, 14, 19). We demonstrate this in our study by using the BLUE protocol, realizing that this is outside of its intended use, which provides a highly sensitive test to detect alveolar consolidation, but offers no means to differentiate the underlying etiology. This follows logically from the fact all patients had (bi-) basal consolidation thus resulting in pneumonia as final diagnosis regardless of the anterior lung examination.

Other scoring tools such as the Clinical Pulmonary Infection Score (using a scoring system based on vital parameters, culture, and imaging) were developed to help clinicians establish the diagnosis of pneumonia. However, several studies have demonstrated that its diagnostic accuracy is moderate at best (20, 21). More recently, an observational study in postcardiothoracic surgery patients showed that a simplified version of this score (including fewer parameters and replacing the CXR score with color Doppler imaging) outperformed the original version (14). We report an even higher diagnostic accuracy with a decision tree where the score is applied after a preselection is made on ultrasound parameters. This further

TABLE 3.
Diagnostic Accuracy of Ultrasound Signs, Protocols, and Clinical Scores

Diagnostic Modality	Accuracy	Sensitivity	Specificity	Positive Predictive Value	Negative Predictive Value	Positive Likelihood Ratio	Negative Likelihood Ratio
Air bronchogram	76 (67–83)	45 (31–60)	99 (92–100)	96 (76–99)	71 (65–76)	31.1 (4.3–223)	0.6 (0.4–0.7)
Color Doppler	78 (68–85)	90 (79–97)	68 (56–79)	68 (59–75)	90 (80–96)	2.8 (2.0–4.0)	0.1 (0.06–0.3)
Decision tree	86 (78–92)	86 (74–94)	86 (75–93)	81 (71–89)	90 (81–94)	6.0 (3.3–11.0)	0.2 (0.1–0.3)
Simplified Clinical Pulmonary Infection Score	66 (57–74)	41 (28–56)	84 (73–92)	66 (50–78)	66 (60–71)	2.6 (1.4–4.9)	0.7 (0.5–0.9)
Lung Ultrasound Clinical Pulmonary Infection Score	76 (67–83)	68 (54–81)	81 (70–90)	73 (61–82)	78 (70–84)	3.4 (2.1–5.6)	0.4 (0.3–0.6)
Bedside Lung Ultrasound in Emergency	43 (34–52)	100 (93–100)	0 (0–5)	42 (NA)	NA	1	NA

NA = not available.
Values for sensitivity, specificity, positive predictive value, and negative predictive value are presented as percent with 95% CI.
Values for positive likelihood ratio and negative likelihood ratio are presented as likelihood with 95% CI.

Copyright © 2022 by the Society of Critical Care Medicine and Wolters Kluwer Health, Inc. All Rights Reserved.

emphasizes the added value of extended lung ultrasonography assessment. Interestingly, in our study, the lusCPIS on itself yielded a lower sensitivity but higher specificity compared with the study in which the score was established (14). We reason that this could be due to the differences in study population (ventilated, post cardiothoracic surgery vs general ICU population with consolidation on CXR), which could impact the nonlung ultrasound categories of the score. Additionally, we hypothesize that we might have used a stricter definition for the presence of flow, determining it to be "absent" more often. The latter highlights an important consideration of expertise necessary for adequate image acquisition and the question of image reproducibility. While we did not evaluate the former in our study, we were able to demonstrate that both flow measurements and assessment of dynamic air bronchograms had substantial interrater and intrarater agreement. To our knowledge, this is the first study that evaluated this, which provides a strong argument in favor of extended lung ultrasound variables as a differentiating tool for pneumonia and atelectasis. Nevertheless, it should be noted that the reproducibility was evaluated in experienced researchers and could potentially be lower in less experienced hands.

Given the good reproducibility, the evaluated signs and decision tree could also be used repeatedly over the course of the disease to monitor disease progression and effect of treatment. Recent studies have in fact shown that standard lung ultrasound is a viable tool in this regard, but studies including extended lung ultrasound as a monitoring tool are currently lacking and need to be conducted (12, 22).

An important consideration of our study is that the proposed decision tree relies on bedside available measurements for differentiation of pneumonia and atelectasis. This is in stark contrast with the sCPIS score, which in part relies on more time-consuming variables such as gram-stain coloring and bacterial growth in blood or sputum cultures. Intuitively, this poses an important advantage as it could potentially reduce the time until antibiotic treatment is started or discontinued/withheld. One could incorporate this as a first decision step and if the clinical setting allows to withhold antibiotics or uncertainty in the diagnosis remains, make use of culture results and the ventilator-associated pneumonia lung ultrasound score (11). Whether our decision tree or such a combined approach results in quantifiable differences in clinical outcomes such as time spent on a ventilator, ICU length of stay, or even mortality is an important question and needs to be investigated in future studies.

Another important aspect of our study is understanding the physiologic meaning of the ultrasonographic signs used. For example, absence of flow in consolidated lung tissue does not per se prove atelectasis to be the underlying condition but rather demonstrates a lower degree of shunting in that region compared with preserved flow (23). Working from the premise that in obstructive circumstances, alveolar filling with air becomes more difficult than in nonobstructive etiologies, thus causing more local hypoxia and more vasoconstriction, the diagnosis of atelectasis becomes more likely but is not proven (13). Identically, the presence of the dynamic air bronchogram is does not prove the presence of pneumonia, but rather indicates fluid filled, yet patent airways, which is more likely to occur in pneumonia (9). In the same vein, it should be noted that we distinguished pneumonia and atelectasis as overarching categories, without differentiating between community-acquired pneumonia, hospital-acquired pneumonia, or ventilator-associated pneumonia and resorption-, compression-, or obstructive atelectasis, respectively. As their underlying pathophysiology differs, this could also hold true for the resulting ultrasonographic patterns, as has been suggested in previous literature (11, 13, 15). These nuances, in addition to other ultrasonographic findings such as the quality and quantity of pleural effusion, type of static air bronchogram, or contrast-enhanced ultrasound could potentially support the differentiation of a pulmonary consolidation seen on CXR even further and should be investigated in future studies.

Taken all the above into consideration, we reason that an extended lung ultrasound approach incorporating assessment of flow and the dynamic air bronchogram is a useful tool for clinical practice and allows for a quick bedside differentiation of pneumonia from atelectasis.

LIMITATIONS

This study bears several important limitations. First, examination was always performed by researchers

Copyright © 2022 by the Society of Critical Care Medicine and Wolters Kluwer Health, Inc. All Rights Reserved.

experienced in ultrasonography. While basic lung ultrasound has a steep learning curve, detection of dynamic air bronchograms and correct interpretation of flow signals requires a substantial amount of practice in our experience. Second, diagnosis of pneumonia on the ICU is difficult and certainty is only guaranteed by postmortem analyses (24). As a surrogate, we therefore relied on the consensus diagnosis of two clinicians, which is in line with two previous studies evaluating diagnostic tools for pneumonia (14, 25). While this method is commonly used due to its feasibility and accuracy, more precise alternatives, that is, a gold standard, that does not rely on postmortem analysis is needed. In the meantime, we should keep in mind that an established diagnosis is not definitive and if used as reference test, it can impact accuracy of the index test. Third, although we included a heterogeneous ICU population to increase generalizability, the occurrence of pneumonia was as expected high, which influences predictive values such as the positive predictive value and negative predictive value. However, the sensitivity, specificity, and likelihood ratios are less affected. Fourth, in line with the previous point, in our ICU, selective digestive decontamination is standard procedure. This might impact the incidence of pneumonia due to early antibiotic intervention but also due to the high frequency of cultures taken. Fifth, it should be noted that sCPIS was validated in ventilated patients but in our study also calculated in nonventilated patients. This could have resulted in a lowers diagnostic accuracy of the test in our study. Last, this was a single-center observational study, potentially limiting the external validity. Nevertheless, multiple operators participated in image acquisition and the relatively large sample size compared with previous studies could mitigate this issue.

STRENGTHS

This study also has some important strengths. First, we included a heterogeneous and relatively large sample size when compared with previous studies and several different researchers performed the ultrasound measurement. This increases the external validity of the study. Second, to our knowledge, this is the first study to incorporate air bronchogram and color Doppler together for the diagnosis of pneumonia. Third, the proposed decision tree only relies on bedside and quickly available information to reach a diagnosis.

INTERPRETATION

In ICU patients with pulmonary consolidation on CXR, an extended lung ultrasound protocol based on the evaluation of air bronchograms and measurements of pulsatile flow is an accurate and directly bedside available tool to differentiate pneumonia and atelectasis. It outperforms standard lung ultrasound and clinical scores.

1 Department of Intensive Care Medicine, Amsterdam University Medical Centers, location VUmc, Amsterdam, The Netherlands.

2 Amsterdam Leiden Intensive care Focused Echography (ALIFE, www.alifeofpocus.com), Amsterdam, The Netherlands.

3 Amsterdam Cardiovascular Sciences Research Institute, Amsterdam UMC, Amsterdam, The Netherlands.

Supplemental digital content is available for this article. Direct URL citations appear in the printed text and are provided in the HTML and PDF versions of this article on the journal's website (http://journals.lww.com/ccmjournal).

Dr. Haaksma takes responsibility for the content of the article, including the data and analysis. Drs. Haaksma, de Grooth, Jonkman, Girbes, Heunks, and Tuinman were responsible for the conception and design of the work. Drs. Haaksma, Smit, Heldeweg, Nooitgedacht, and Tuinman were responsible for acquisition and or analysis of the data. Dr. Haaksma was responsible for building the database and drafting the article, and all authors provided critical revisions for it. All authors read and approved the final article and ensured that questions related to the accuracy or integrity of any part of the work were investigated and resolved.

Drs. Jonkman and Heunks received funding from Liberate Medical. Dr. Heunks also received funding from Getinge Critical Care and Fisher and Paykel. Dr. Tuinman disclosed departmental work. The remaining authors have disclosed that they do not have any potential conflicts of interest.

Approval was given by the local ethics committee (Medisch Ethische Toetsings Commissie) under study number 2016.465.

Consent for publication was retrieved by all subjects included in the study.

The datasets used and/or analyzed during the current study are available from the corresponding author on reasonable request.

For information regarding this article, E-mail: m.haaksma@amsterdamumc.nl

REFERENCES

1. Henschke CI, Pasternack GS, Schroeder S, et al: Bedside chest radiography: Diagnostic efficacy. *Radiology* 1983; 149:23–26

Copyright © 2022 by the Society of Critical Care Medicine and Wolters Kluwer Health, Inc. All Rights Reserved.

2. Ferrer M, Torres A: Epidemiology of ICU-acquired pneumonia. *Curr Opin Crit Care* 2018; 24:325–331
3. Li G, Cook DJ, Thabane L, et al; PROTECT Investigators for the Canadian Critical Care Trials Group, and the Australian and New Zealand Intensive Care Society Clinical Trials Group: Risk factors for mortality in patients admitted to intensive care units with pneumonia. *Respir Res* 2016; 17:80
4. Arts L, Lim EHT, van de Ven PM, et al: The diagnostic accuracy of lung auscultation in adult patients with acute pulmonary pathologies: A meta-analysis. *Sci Rep* 2020; 10:7347
5. Winkler MH, Touw HR, van de Ven PM, et al: Diagnostic accuracy of chest radiograph, and when concomitantly studied lung ultrasound, in critically ill patients with respiratory symptoms: A systematic review and meta-analysis. *Crit Care Med* 2018; 46:e707–e714
6. Touw HR, Parlevliet KL, Beerepoot M, et al: Lung ultrasound compared with chest radiograph in diagnosing postoperative pulmonary complications following cardiothoracic surgery: A prospective observational study. *Anaesthesia* 2018; 73:946–954
7. Xirouchaki N, Magkanas E, Vaporidi K, et al: Lung ultrasound in critically ill patients: Comparison with bedside chest radiography. *Intensive Care Med* 2011; 37:1488–1493
8. Lichtenstein DA, Mezière GA: Relevance of lung ultrasound in the diagnosis of acute respiratory failure: The BLUE protocol. *Chest* 2008; 134:117–125
9. Lichtenstein D, Mezière G, Seitz J: The dynamic air bronchogram. *Chest* 2009; 135:1421–1425
10. Yang P-C: Color Doppler ultrasound of pulmonary consolidation. *Eur J Ultrasound* 1996; 3:169–198
11. Mongodi S, Via G, Girard M, et al: Lung ultrasound for early diagnosis of ventilator-associated pneumonia. *Chest* 2016; 149:969–980
12. Bouhemad B, Dransart-Rayé O, Mojoli F, et al: Lung ultrasound for diagnosis and monitoring of ventilator-associated pneumonia. *Ann Transl Med* 2018; 6:418
13. Yuan A, Yang PC, Lee L, et al: Reactive pulmonary artery vasoconstriction in pulmonary consolidation evaluated by color Doppler ultrasonography. *Ultrasound Med Biol* 2000; 26:49–56
14. Dureau P, Bouglé A, Melac AT, et al: Colour Doppler ultrasound after major cardiac surgery improves diagnostic accuracy of the pulmonary infection score in acute respiratory failure: A prospective observational study. *Eur J Anaesthesiol* 2019; 36:676–682
15. Xirouchaki N, Pediaditis M, Proklou A, et al: Tree-like colour Doppler in diagnosing pneumonia in critically ill: A picture is worth a thousand words. *Intensive Care Med* 2018; 44:494–495
16. Luna CM, Blanzaco D, Niederman MS, et al: Resolution of ventilator-associated pneumonia: Prospective evaluation of the clinical pulmonary infection score as an early clinical predictor of outcome. *Crit Care Med* 2003; 31:676–682
17. Buderer NM: Statistical methodology: I. Incorporating the prevalence of disease into the sample size calculation for sensitivity and specificity. *Acad Emerg Med* 1996; 3:895–900
18. Šimundić A-M: Measures of diagnostic accuracy: Basic definitions. *EJIFCC* 2009; 19:203–211
19. Hongrattana G, Reungjui P, Tumsatan P, et al: Incidence and risk factors of pulmonary atelectasis in mechanically ventilated trauma patients in ICU: A prospective study. *Int J Evid Based Healthc* 2019; 17:44–52
20. Gaudet A, Martin-Loeches I, Povoa P, et al; TAVeM Study Group: Accuracy of the clinical pulmonary infection score to differentiate ventilator-associated tracheobronchitis from ventilator-associated pneumonia. *Ann Intensive Care* 2020; 10:101
21. Schurink CAM, Nieuwenhoven CAV, Jacobs JA, et al: Clinical pulmonary infection score for ventilator-associated pneumonia: Accuracy and inter-observer variability. *Intensive Care Med* 2004; 30:217–224
22. Bouhemad B, Liu ZH, Arbelot C, et al: Ultrasound assessment of antibiotic-induced pulmonary reaeration in ventilator-associated pneumonia. *Crit Care Med* 2010; 38:84–92
23. Mongodi S, Bouhemad B, Iotti GA, et al: An ultrasonographic sign of intrapulmonary shunt. *Intensive Care Med* 2016; 42:912–913
24. Klompas M: Does this patient have ventilator-associated pneumonia? *JAMA* 2007; 297:1583–1593
25. Sekiguchi H, Schenck LA, Horie R, et al: Critical care ultrasonography differentiates ARDS, pulmonary edema, and other causes in the early course of acute hypoxemic respiratory failure. *Chest* 2015; 148:912–918

Copyright © 2022 by the Society of Critical Care Medicine and Wolters Kluwer Health, Inc. All Rights Reserved.