Managing Cardiac Arrest Using Ultrasound

Michael Gottlieb, MD*; Stephen Alerhand, MD

*Corresponding Author. E-mail: michaelgottliebmd@gmail.com.

0196-0644/$-see front matter
Copyright © 2022 by the American College of Emergency Physicians.
https://doi.org/10.1016/j.annemergmed.2022.09.016

Continuing Medical Education exam for this article is available at http://www.acep.org/ACEPeCME/.

[Ann Emerg Med. 2023;81:532-542.]

INTRODUCTION

The emergency department (ED) is the main receiving area for all out-of-hospital cardiac arrests and the setting for approximately 10% of all in-hospital cardiac arrests.[1] The rate of survival-to-discharge among out-of-hospital cardiac arrests is approximately 9%, though it may be up to 35% in those experiencing cardiac arrest while in the ED.[2,3] Patients in cardiac arrest require rapid, targeted interventions and resuscitative efforts, and those who have lost pulses in the ED have a greater likelihood of reversible causes.[1] However, the cause can be challenging to diagnose by the inherently limited history and physical examination.

Several guidelines have suggested a role for point-of-care ultrasound (POCUS) in cardiac arrest.[4-6] However, there have been concerns regarding prolonged interruptions in chest compressions when using this tool.[7-9] Additionally, several unique POCUS protocols have been posited that vary in the diagnoses they evaluate for and the way they do so (Table). Therefore, there is a need better to understand the optimal role of POCUS in cardiac arrest. This paper seeks to distill key facets of the application of POCUS in cardiac arrest based on the current literature and years of practice.

MINIMIZING INTERRUPTIONS IN CHEST COMPRESSIONS

High-quality chest compressions are a critical component of cardiopulmonary resuscitation, so it is important to minimize the duration of pauses between compression cycles.[10] Guidelines recommend that these pauses not exceed 10 seconds in order to maintain cerebral perfusion.[11] One potential concern with POCUS in cardiac arrest has been the prolongation of these pauses, with retrospective studies reporting a 4- to 8-second increase in pause duration.[7-9] However, a recent prospective study reported no difference in pause duration when one ultrasound was performed within a single pause, with delays occurring only when more than one ultrasound was performed during a single pause.[12] Several techniques can help avoid this issue (Figure 1). First, the most experienced sonographer should conduct the scan.[7,8] Second, the POCUS scan should be performed by a clinician who is not also burdened with the responsibilities of a code team leader.[13] Third, noncardiac applications (eg, lung, airway, deep venous thrombosis) should be performed during ongoing compressions. Fourth, the transducer should be placed on the chest to identify the optimal cardiac window prior to pausing compressions.[12,13] One study of simulated cardiac arrest scenarios supported the parasternal long-axis over the subxiphoid view.[14] Fifth, the sonographer should focus on recording a clip, then wait until after compressions have resumed to analyze that clip.[13] Sixth, a towel should be kept nearby for immediately wiping off the ultrasound gel to avoid a slippery surface for chest compressions. Finally, there should be a designated timer counting down from 10 seconds to ensure chest compressions resume promptly.[13]

DIAGNOSTIC APPLICATIONS IN CARDIAC ARREST

Cardiac Tamponade

The largest multicenter study prospectively evaluating transthoracic echocardiography (TTE) in cardiac arrest found that cardiac tamponade was present in 4% of cases (Figure 2; Video E1, available at http://www.annemergmed.com.)[15] Evidence suggests that emergency physicians are able to visualize pericardial effusions with 88% to 96% sensitivity and 98% specificity, including in pulseless electrical activity and near-pulseless electrical activity states.[16-18] In noncardiac arrest patients with pericardial effusion, findings suggestive of tamponade include diastolic right ventricular collapse (48% to 60% sensitive, 75% to 90% specific), systolic right atrial collapse (50% to 100% sensitive, 33% to 100% specific), and sonographic pulsus paradoxus.[19-36] The lack of right-sided chamber collapse

Table. Point-of-care ultrasound protocols in cardiac arrest.

Protocol	Components
Cardiac Arrest Sonographic Assessment (CASA)[8,151]	• Cardiac (cardiac tamponade, right heart strain, cardiac activity) • Lung (pneumothorax) • FAST
Cardiac Arrest Ultrasound Examination (CAUSE)[152]	• Cardiac (cardiac tamponade, hypovolemia, and massive PE) • Lung (pneumothorax)
Core Ultrasound in Resuscitation (CURE)[153]	• Noncardiac (FAST, AAA, DVT, confirm ETT position, and pneumothorax) • Cardiac TTE (cardiac contractility, ventricular arrhythmia, aortic emergency, intracardiac thrombus, maximal compression site, and hypovolemia) • Post-ROSC TEE (preload, cardiac and valvular function, procedural guidance)
Focused Echocardiographic Evaluation in Life Support (FEEL)[154]	• Cardiac (cardiac activity, ventricular function, right ventricular dilatation, and pericardial effusion)
Focused Echocardiographic Evaluation in Resuscitation (FEER)[155]	• Cardiac (cardiac activity, pericardial effusion/cardiac tamponade, hypovolemia, and massive PE)
Pulseless Electrical Activity or Pulmonary-Epigastric-Abdominal[156]	• Cardiac (pericardial effusion, cardiac activity, left ventricular size/hypertrophy/contractility, right ventricular size/contractility, and IVC filling) • Lung (pneumothorax, pleural effusion, and pulmonary edema) • Abdomen and other (thoracic and abdominal aortic aneurysm or dissection, peritoneal effusion, bowel obstruction or perforation, and DVT)
Point-of-Care Ultrasound in Cardiorespiratory Arrest (POCUS-CA)[157]	• Cardiac (cardiac activity, chest compression efficacy, pericardial effusion/cardiac tamponade, and PE) • Lung (pneumothorax) • Abdominal (peritoneal effusion and AAA) • Femoral (DVT)
Rapid Cardiac POCUS in Pulmonary-Epigastric-Abdominal Arrest[158]	• Cardiac (contractility, pericardial effusion, right ventricular dilation with small dynamic left ventricle, underfilled right ventricle with the small dynamic left ventricle)
Reversible Causes in Cardiovascular Collapse at the Emergency Department Using Ultrasonography (REVIVE-US)[159]	• Cardiac (cardiac activity and cardiac tamponade) • FAST • Aorta (dissection or aneurysm) • DVT • Lung (pneumothorax) • Post-ROSC Cardiac (contractility, right ventricular dilation, and regional wall motion abnormalities)
Sequential Emergency Scanning Assessing Mechanism or Origin of Shock of Indistinct Cause (SESAME)[160,161]	• Lung (pulmonary edema and pneumothorax) • DVT • Abdomen (peritoneal effusion) • Cardiac (cardiac tamponade, contractility, right ventricular dilatation, and ventricular fibrillation)
Sonography in Hypotension and Cardiac Arrest (SHoC)[162-164]	• Cardiac (cardiac tamponade, right ventricular dysfunction, cardiac activity, and ventricular size) • Lung (pneumothorax and pleural effusion) • IVC (diameter and respiratory variation) • Airway (ETT confirmation) • DVT • Abdomen (AAA and peritoneal effusion)
Ultrasound Circulation-Airway-Breathing (US-CAB)[165,166]	• Cardiac (contractility, cardiac tamponade, right ventricular dilatation, septal dyskinesia, and right-sided chamber flattening suggestive of hypovolemia) • IVC (diameter and respirophasic collapsibility) • Trachea (ETT confirmation) • Lung (pneumothorax and single lung intubation)

AAA, abdominal aortic aneurysm; *BLS,* basic life support; *DVT,* deep venous thrombosis; *ETT,* endotracheal tube; *FAST,* focused assessment with sonography in trauma; *IVC,* inferior vena cava; *PE,* pulmonary embolism; *ROSC,* return of spontaneous circulation; *TEE,* transesophageal echocardiogram; *TTE,* transthoracic echocardiogram.

1. Have the most experienced sonographer perform the scan.
2. Someone besides the team leader should perform the scan (when possible).
3. Perform non-cardiac applications (e.g., lung, airway, deep venous thrombosis) while compressions are ongoing.
4. Place the transducer on the chest to identify the optimal cardiac window prior to pausing compressions.
5. Focus on recording the clip, then wait to analyze the clip until after compressions have resumed.
6. Keep a towel nearby to wipe off ultrasound gel immediately after the scan.
7. Have a designated timer count down from 10 seconds to avoid prolonged scanning time.

Figure 1. Strategies to minimize the duration of chest compression pauses during cardiac arrest.

carries up to a 90% negative predictive value for tamponade in noncardiac arrest cases.[23] Importantly, due to the absence of normal forward flow and cardiovascular pressures in cardiac arrest, right-sided chamber collapse is less reliable for assessing whether the pericardial effusion is responsible for the hemodynamic collapse in this patient population.

Larger effusions are more often associated with right-sided chamber collapse and hemodynamic compromise.[37,38] However, the development of tamponade physiology depends on the rate of effusion accumulation and pericardial compliance.[35,36] Even a rapidly accumulating effusion of only 50 mL can overcome the visceral pericardium's stretch limit and lead to tamponade.[39,40] Consequently, drainage of even a small amount of fluid can relieve tamponade because of the steep pericardial pressure-volume relationship.[35,41] One study found that patients in cardiac arrest who underwent pericardiocentesis for suspected tamponade demonstrated a higher survival-to-discharge than all other patients (15% versus 1%).[15] Therefore, when a pericardial effusion is identified and there is heightened suspicion for tamponade, pericardial drainage should be performed.

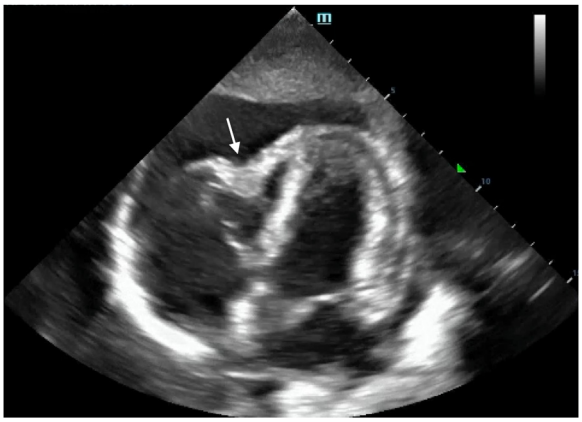

Figure 2. A pericardial effusion with the diastolic right ventricular collapse in the subxiphoid view is suggestive of cardiac tamponade; the arrow points to right ventricular collapse.

Massive Pulmonary Embolism

Evidence indicates that pulmonary embolism may be the cause in 2% to 5% of cardiac arrests (Figure 3, Video E2).[15,42] Echocardiographic findings suggestive of PE include a right-sided clot-in-transit and acute right ventricular dysfunction (eg, enlarged right ventricle, septal dyskinesia).[43] However, these findings are more suggestive of PE early in the arrest, whereas clot-in-transit and right ventricular dilation appear commonly later in the arrest regardless of whether a PE is present. Experimental models have demonstrated right ventricular enlargement in cardiac arrest and following the return of spontaneous circulation from various etiologies (eg, hypovolemia, hyperkalemia, arrhythmia, hypoxia) in the absence of PE.[44-46] Moreover, the degree of septal dyskinesia (ie, "D sign") from massive PE may be greatest at the onset of arrest, as it can decrease over time regardless of intervention.[46,47] Of note, these findings can also be observed in patients with chronic right ventricular dysfunction, such as pulmonary hypertension.[48,49] However, patients with chronic right ventricular dysfunction will typically have a thickened right ventricular free wall (diameter >5 mm) from hypertrophy developed over time.[43,50] Additionally, a right-sided clot can be quite common in cardiac arrest as sequelae of the low-flow state, with data suggesting that new thrombus formation may occur as early as 6 minutes after the onset of arrest.[51,52] Therefore, although a clot-in-transit or right ventricular dysfunction may point toward a PE, these findings should be interpreted with caution later in the cardiac arrest unless a suggestive clinical history (eg, pleuritic chest pain, dyspnea) was reported preceding the arrest or a deep venous thrombosis is diagnosed (Figure 4, Video E3).[53-55]

Ventricular Fibrillation

Ventricular fibrillation is typically diagnosed on the cardiac monitor. However, it may be challenging to decipher fine ventricular fibrillation, particularly if the pads are not well placed or the patient has increased soft tissue between the pads and the heart. In these instances, POCUS

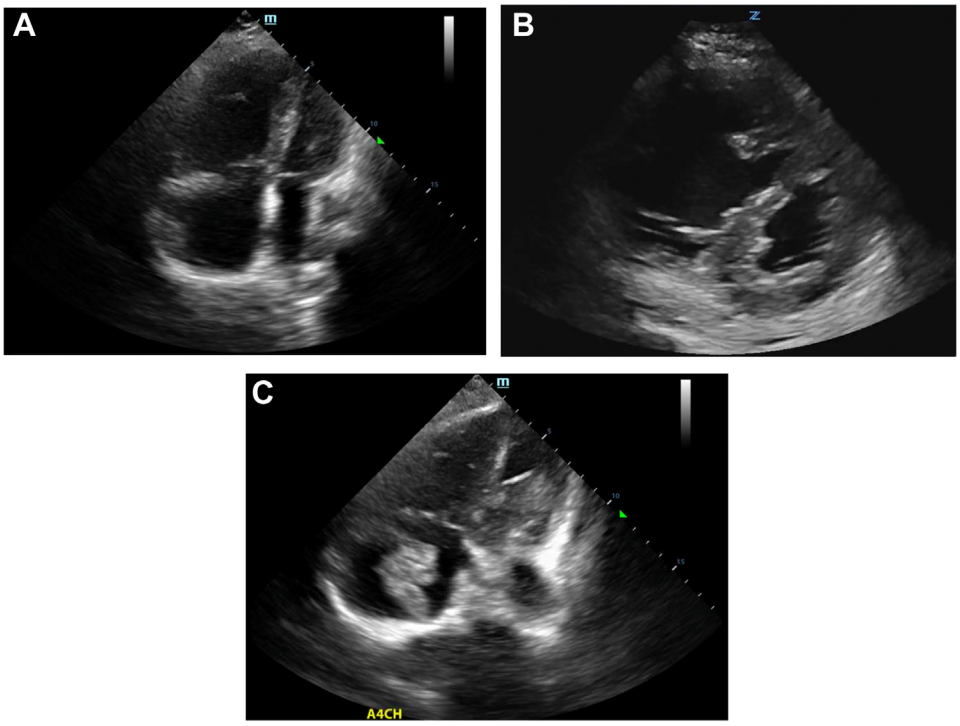

Figure 3. *A*, Right ventricular dilation in the apical 4-chamber view. *B*, Septal dyskinesia (ie, "D sign") in the parasternal short-axis view. *C*, Clot-in-transit in the apical 4-chamber view.

may detect fine ventricular fibrillation that would otherwise remain diagnosed as asystole (Video E4).[56-59] Several studies have demonstrated discordance between ultrasound and electrocardiography for recognizing ventricular fibrillation.[60-62] Limited data demonstrate that ventricular fibrillation identified by ultrasound (in the absence of electrocardiography evidence) has similar outcomes to those diagnosed by electrocardiography.[60-62] Ultrasound may thereby have the ability to identify patients who would benefit from defibrillation in cases where current advanced cardiac life support guidelines would not recommend it. Given the significantly higher survival for patients in ventricular fibrillation than those with nonshockable rhythms, using ultrasound to identify ventricular fibrillation may improve survival.[63]

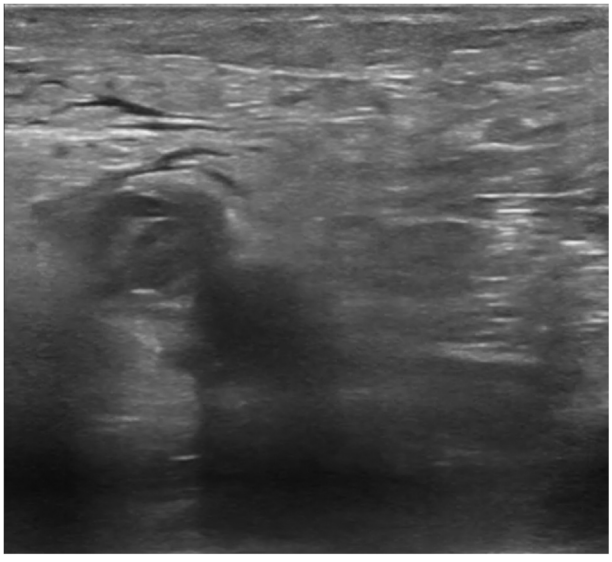

Figure 4. A noncompressible femoral vein with a visible clot indicating deep venous thrombosis.

Hypovolemia

Hypovolemia may be suggested by underfilled and easily collapsible ventricles, indicating a role for intravenous fluids or blood products depending on the cause (Video E5).[64] Inferior vena cava diameter and respirophasic variability have only shown moderate strength correlation with central venous pressure under normal circumstances.[65] In cardiac arrest patients receiving positive-pressure ventilation, the associated positive intrathoracic pressure makes the inferior vena cava more likely to be dilated.[50,66-68] Therefore, a plethoric inferior vena cava carries minimal diagnostic utility in these situations.

Incorrect Endotracheal Tube Placement

Point-of-care ultrasound can also be used to confirm endotracheal tube location after intubation

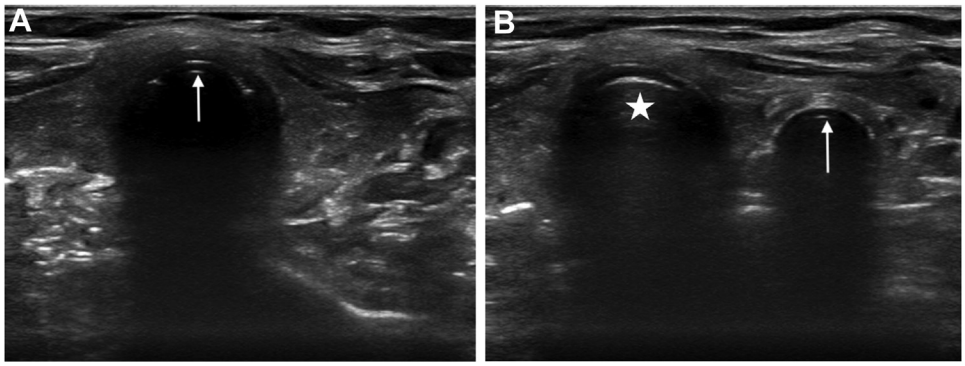

Figure 5. *A*, Transtracheal ultrasound demonstrating tracheal intubation; arrow represents the endotracheal tube. *B*, Transtracheal ultrasound demonstrating esophageal intubation; arrow represents the endotracheal tube in the esophagus, and the star identifies an empty trachea.

(Figure 5).[69,70] End-tidal capnography can be less accurate in cardiac arrest because of low cardiac output, reduced pulmonary blood flow, and administration of peripheral vasopressors.[71-74] Although low or absent expired carbon dioxide could signal esophageal intubation, it may also indicate inadequate circulation, a prolonged arrest time, hypothermia, or a substantial ventilation/perfusion mismatch.[75] By comparison, POCUS is 99% sensitive and 97% specific for confirming endotracheal intubation.[76] This accuracy remains consistent regardless of sonographic technique, transducer choice, or endotracheal tube size.[76-84] Moreover, this POCUS evaluation can be performed during ongoing chest compressions and would not prolong pauses. It also does not necessitate providing positive-pressure ventilations, which increases the risk of gastric insufflation and aspiration. As the endotracheal tube position can be displaced during transport or as a result of cardiopulmonary resuscitation, transtracheal ultrasound can also assess proper endotracheal tube depth, whereas lung ultrasound can evaluate for endobronchial placement.[85-94] Because absent lung sliding can appear in both mainstem intubation and pneumothorax, detecting lung pulse is useful to help identify the former.[91-94]

Pneumothorax

Point-of-care ultrasound is 91% sensitive and 99% specific for identifying a pneumothorax in the supine patient (Figure 6, Video E6).[95] A single view along the midclavicular line in the third intercostal space is likely sufficient to identify a clinically significant pneumothorax.[96] Traditionally, it has been taught that a needle thoracostomy is warranted in cardiac arrest if there is a concern for pneumothorax. However, this procedure risks injury to both patient and clinician, so it is reasonable to first perform rapid lung POCUS to assess for the presence or absence of lung sliding. POCUS can also determine the depth of the pleural interface to ensure the needle length is sufficient to reach the target.[97,98]

Intraabdominal Pathology and Free Fluid

In a female patient of child-bearing age presenting in cardiac arrest, POCUS demonstrating abdominal free fluid can suggest a ruptured ectopic pregnancy, which can guide

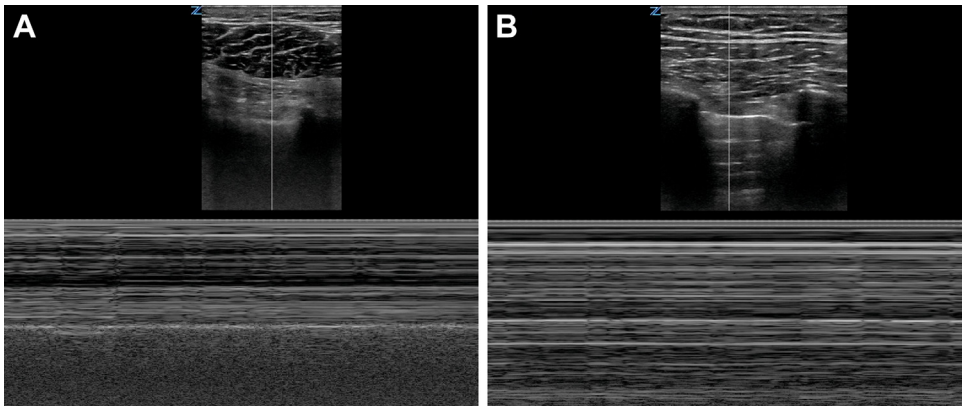

Figure 6. *A*, Seashore sign in the normal lung using M-mode. *B*, Barcode/stratosphere sign in pneumothorax using M-mode.

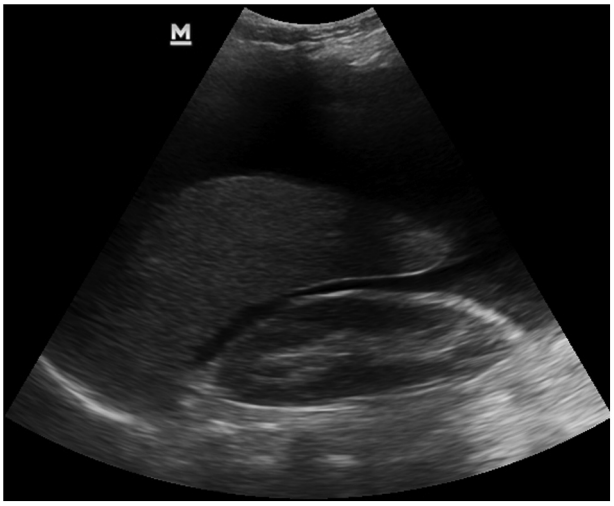

Figure 7. Free fluid in the right upper quadrant on abdominal ultrasound.

subsequent management if the return of spontaneous circulation is obtained (Figure 7, Video E7).[99] Clinicians can also use POCUS to evaluate for aortic dissection or ruptured abdominal aortic aneurysm, as well as intraabdominal free fluid, in the context of possible trauma.[100,101]

PROGNOSTIC APPLICATIONS IN CARDIAC ARREST

A 2021 meta-analysis reported that cardiac standstill in traumatic arrest was 91% sensitive and 98% specific for failing to achieve return of spontaneous circulation.[102] Of note, no patients with cardiac standstill in traumatic arrest survived to discharge.[102] Another meta-analysis in atraumatic, nonshockable cardiac arrest reported that cardiac standstill was 92% sensitive and 60% specific for failing to achieve return of spontaneous circulation.[103] Cardiac activity on POCUS had an odds ratio of 10.3 for survival-to-admission and 8.0 for survival-to-discharge.[103] The predictive utility of cardiac standstill has remained consistent regardless of the initial electrocardiographic rhythm.[57,60] Experts have defined organized cardiac activity as "movement of the myocardium with change in the size of the ventricular cavity and synchronized movement of the ventricular wall."[104] Data among expert sonographers have demonstrated excellent interrater reliability in assessing for cardiac standstill; however, there is greater variability in this interpretation among less-experienced users (62% self-reporting none or basic ultrasound skill levels in this data set).[105,106] If the cardiac motion is detected in the absence of a pulse, a stronger ejection fraction is associated with an increased likelihood of return of spontaneous circulation.[107] Alternatively, right ventricular dysfunction after return of spontaneous circulation has demonstrated an association with decreased survival rates and worse neurological outcomes.[108]

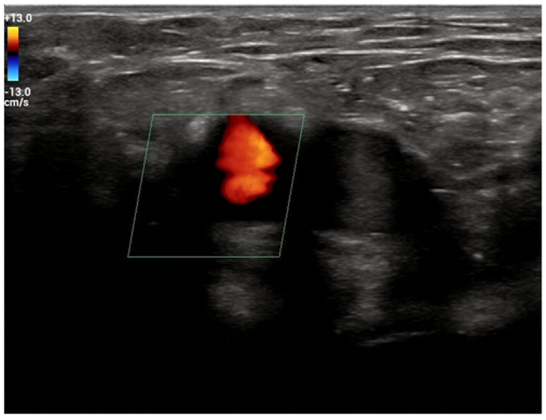

Figure 8. Visible pulsatile flow using color Doppler.

NEWER APPLICATIONS

POCUS Pulse Checks

Evidence suggests that manual pulse checks during cardiac arrest are suboptimal in accuracy and time to performance.[109-115] In comparison, POCUS can more rapidly check for a pulse, using B-mode or color Doppler to assess the pulsatility (or lack thereof) of central arteries and pulsed wave Doppler to assess for quantifiable pulsatile flow (Figure 8, Video E8).[116-118] To shorten the time for assessment, we recommend locating the carotid or femoral arteries prior to the pulse check. Evidence suggests that this technique is feasible, accurate, reliable, quickly performed, and easily learned by emergency physicians.[116-124] However, it remains unclear whether the presence of a pulse by Doppler alone is sufficient to indicate perfusion. Further data are needed to determine the most appropriate role of Doppler for pulse detection.

Transesophageal Echocardiography

Expert guidelines support a limited 3-view protocol for incorporating transesophageal echocardiography (TEE) into cardiac arrest management.[125] Compared with TTE, placement of the TEE transducer directly into the esophagus provides continuous cardiac visualization during ongoing chest compressions and shortens pulse check duration.[126] Transesophageal echocardiography also overcomes obstacles to TTE transducer placement, such as chest compressor hands, defibrillator pads, and automatic compression devices. Because of the transducer's closer proximity to the heart, TEE also produces higher-quality images while obviating patient

factors such as obesity and gastric insufflation from positive-pressure ventilation. Altogether, this allows TEE to better evaluate for organized cardiac contractility (Video E9), identify shockable rhythms (ie, fine ventricular fibrillation and ventricular tachycardia), assess left ventricular systolic function, diagnose reversible causes of cardiac arrest, evaluate chest compression quality and location (Video E10), guide resuscitative procedures, and monitor the response to interventions.[61,127-143] A 2021 systematic review consisting of both in- and out-of-hospital cardiac arrests found that TEE identified reversible causes in 41% of patients.[144] Evidence suggests that emergency physicians with competency in TTE can successfully perform TEE following a short, structured simulation-based training program.[125,140,145-148] Transesophageal echocardiography is also safe, with 2 studies of over 17,000 non-arrest patients reporting a complication rate of only 0.2%.[149,150]

CONCLUSION

In conclusion, POCUS is a highly versatile tool for evaluating various potentially treatable etiologies in cardiac arrest. However, it is important to use proper technique and minimize delays in chest compressions. Nevertheless, in appropriately trained hands, POCUS can be integrated into cardiac arrest care and provide more targeted management for resuscitation in these critically ill patients.

Supervising editor: Steven M. Green, MD. Specific detailed information about possible conflict of interest for individual editors is available at https://www.annemergmed.com/editors.

Author affiliations: From the Department of Emergency Medicine, Rush University Medical Center, Chicago, IL (Gottlieb); Department of Emergency Medicine, Rutgers New Jersey Medical School, Newark, NJ (Alerhand).

Authorship: All authors attest to meeting the four ICMJE.org authorship criteria: (1) Substantial contributions to the conception or design of the work; or the acquisition, analysis, or interpretation of data for the work; AND (2) Drafting the work or revising it critically for important intellectual content; AND (3) Final approval of the version to be published; AND (4) Agreement to be accountable for all aspects of the work in ensuring that questions related to the accuracy or integrity of any part of the work are appropriately investigated and resolved.

Funding and support: By *Annals* policy, all authors are required to disclose any and all commercial, financial, and other relationships in any way related to the subject of this article as per ICMJE conflict of interest guidelines (see www.icmje.org). The authors have stated that no such relationships exist.

REFERENCES

1. Mitchell OJL, Edelson DP, Abella BS. Predicting cardiac arrest in the emergency department. *J Am Coll Emerg Physicians Open*. 2020;1:321-326.
2. Yan S, Gan Y, Jiang N, et al. The global survival rate among adult out-of-hospital cardiac arrest patients who received cardiopulmonary resuscitation: a systematic review and meta-analysis. *Crit Care*. 2020;24:61-62.
3. Kimblad H, Marklund J, Riva G, et al. Adult cardiac arrest in the emergency department – A Swedish cohort study. *Resuscitation*. 2022;175:105-112.
4. Link MS, Berkow LC, Kudenchuk PJ, et al. Part 7: adult advanced cardiovascular life support: 2015 American Heart Association guidelines update for cardiopulmonary resuscitation and emergency cardiovascular care. *Circulation*. 2015;132(suppl 2): S444-S464.
5. Soar J, Nolan JP, Böttiger BW, et al. European Resuscitation Council guidelines for resuscitation 2015: Section 3. Adult advanced life support. *Resuscitation*. 2015;95:100-147.
6. Labovitz AJ, Noble VE, Bierig M, et al. Focused cardiac ultrasound in the emergent setting: a consensus statement of the American Society of Echocardiography and American College of Emergency Physicians. *J Am Soc Echocardiogr*. 2010;23:1225-1230.
7. Clattenburg EJ, Wroe P, Brown S, et al. Point-of-care ultrasound use in patients with cardiac arrest is associated prolonged cardiopulmonary resuscitation pauses: a prospective cohort study. *Resuscitation*. 2018;122:65-68.
8. Clattenburg EJ, Wroe PC, Gardner K, et al. Implementation of the Cardiac Arrest Sonographic Assessment (CASA) protocol for patients with cardiac arrest is associated with shorter CPR pulse checks. *Resuscitation*. 2018;131:69-73.
9. Huis In 't Veld MA, Allison MG, Bostick DS, et al. Ultrasound use during cardiopulmonary resuscitation is associated with delays in chest compressions. *Resuscitation*. 2017;119:95-98.
10. Panchal AR, Berg KM, Hirsch KG, et al. 2019 American Heart Association focused update on advanced cardiovascular life support: use of advanced airways, vasopressors, and extracorporeal cardiopulmonary resuscitation during cardiac arrest: an update to the American Heart Association guidelines for cardiopulmonary resuscitation and emergency cardiovascular care. *Circulation*. 2019;140:e881-e894.
11. Kleinman ME, Brennan EE, Goldberger ZD, et al. Part 5: adult basic life support and cardiopulmonary resuscitation quality: 2015 American Heart Association guidelines update for cardiopulmonary resuscitation and emergency cardiovascular care. *Circulation*. 2015;132(suppl 2):S414-S435.
12. Gaspari R, Harvey J, DiCroce C, et al. Echocardiographic pre-pause imaging and identifying the acoustic window during CPR reduces CPR pause time during ACLS – a prospective cohort study. *Resusc Plus*. 2021;6:100094-100095.
13. Gottlieb M, Sundaram T, Olszynski P, et al. Just the facts: point-of-care ultrasound in cardiac arrest. Published online June 30. *CJEM*. 2022;24:579-581.
14. Gaspari RJ, Gleeson T, Alerhand S, et al. A multicenter, prospective study comparing subxiphoid and parasternal views during brief echocardiography: effect on image quality, acquisition time, and visualized anatomy. *J Emerg Med*. 2022;62:648-656.
15. Gaspari R, Weekes A, Adhikari S, et al. Emergency department point-of-care ultrasound in out-of-hospital and in-ED cardiac arrest. *Resuscitation*. 2016;109:33-39.
16. Mandavia DP, Hoffner RJ, Mahaney K, et al. Bedside echocardiography by emergency physicians. *Ann Emerg Med*. 2001;38:377-382.
17. Lanoix R, Leak LV, Gaeta T, et al. A preliminary evaluation of emergency ultrasound in the setting of an emergency medicine training program. *Am J Emerg Med*. 2000;18:41-45.

18. Tayal VS, Kline JA. Emergency echocardiography to detect pericardial effusion in patients in PEA and near-PEA states. *Resuscitation*. 2003;59:315-318.
19. Armstrong WF, Schilt BF, Helper DJ, et al. Diastolic collapse of the right ventricle with cardiac tamponade: an echocardiographic study. *Circulation*. 1982;65:1491-1496.
20. Engel PJ, Hon H, Fowler NO, et al. Echocardiographic study of right ventricular wall motion in cardiac tamponade. *Am J Cardiol*. 1982;50:1018-1021.
21. Singh S, Wann LS, Schuchard GH, et al. Right ventricular and right atrial collapse in patients with cardiac tamponade—a combined echocardiographic and hemodynamic study. *Circulation*. 1984;70:966-971.
22. Singh S, Wann LS, Klopfenstein HS, et al. Usefulness of right ventricular diastolic collapse in diagnosing cardiac tamponade and comparison to pulsus paradoxus. *Am J Cardiol*. 1986;57:652-656.
23. Mercé J, Sagristà-Sauleda J, Permanyer-Miralda G, et al. Correlation between clinical and Doppler echocardiographic findings in patients with moderate and large pericardial effusion: implications for the diagnosis of cardiac tamponade. *Am Heart J*. 1999;138(4 Pt 1):759-764.
24. Guntheroth WG. Sensitivity and specificity of echocardiographic evidence of tamponade: implications for ventricular interdependence and pulsus paradoxus. *Pediatr Cardiol*. 2007;28:358-362.
25. Kronzon I, Cohen ML, Winer HE. Diastolic atrial compression: a sensitive echocardiographic sign of cardiac tamponade. *J Am Coll Cardiol*. 1983;2:770-775.
26. Gillam LD, Guyer DE, Gibson TC, et al. Hydrodynamic compression of the right atrium: a new echocardiographic sign of cardiac tamponade. *Circulation*. 1983;68:294-301.
27. Materazzo C, Piotti P, Meazza R, et al. Respiratory changes in transvalvular flow velocities versus two-dimensional echocardiographic findings in the diagnosis of cardiac tamponade. *Ital Heart J*. 2003;4:186-192.
28. Klein AL, Abbara S, Agler DA, et al. American Society of Echocardiography clinical recommendations for multimodality cardiovascular imaging of patients with pericardial disease: endorsed by the Society for Cardiovascular Magnetic Resonance and Society of Cardiovascular Computed Tomography. *J Am Soc Echocardiogr*. 2013;26:965-1012. e15.
29. Leeman DE, Levine MJ, Come PC. Doppler echocardiography in cardiac tamponade: exaggerated respiratory variation in transvalvular blood flow velocity integrals. *J Am Coll Cardiol*. 1988;11:572-578.
30. Appleton CP, Hatle LK, Popp RL. Cardiac tamponade and pericardial effusion: respiratory variation in transvalvular flow velocities studied by Doppler echocardiography. *J Am Coll Cardiol*. 1988;11:1020-1030.
31. Adler Y, Charron P, Imazio M, et al. 2015 ESC Guidelines for the diagnosis and management of pericardial diseases: the Task Force for the Diagnosis and Management of Pericardial Diseases of the European Society of Cardiology (ESC)Endorsed by: the European Association for Cardio-Thoracic Surgery (EACTS). *Eur Heart J*. 2015;36:2921-2964.
32. Hoit BD, Gabel M, Fowler NO. Cardiac tamponade in left ventricular dysfunction. *Circulation*. 1990;82:1370-1376.
33. Imazio M, De Ferrari GM. Cardiac tamponade: an educational review. Eur Heart J Acute Cardiovasc Care; Published online July 6. 2020;2048872620939341:102-109.
34. Gonzalez MS, Basnight MA, Appleton CP. Experimental pericardial effusion: relation of abnormal respiratory variation in mitral flow velocity to hemodynamics and diastolic right heart collapse. *J Am Coll Cardiol*. 1991;17:239-248.
35. Alerhand S, Adrian RJ, Long B, et al. Pericardial tamponade: a comprehensive emergency medicine and echocardiography review. *Am J Emerg Med*. 2022;58:159-174.
36. Alerhand S, Carter JM. What echocardiographic findings suggest a pericardial effusion is causing tamponade? *Am J Emerg Med*. 2019;37:321-326.
37. Eisenberg MJ, Oken K, Guerrero S, et al. Prognostic value of echocardiography in hospitalized patients with pericardial effusion. *Am J Cardiol*. 1992;70:934-939.
38. Eke OF, Selame L, Gullikson J, et al. Timing of pericardiocentesis and clinical outcomes: is earlier pericardiocentesis better? *Am J Emerg Med*. 2022;54:202-207.
39. Saito Y, Donohue A, Attai S, et al. The syndrome of cardiac tamponade with "small" pericardial effusion. *Echocardiography*. 2008;25:321-327.
40. Tsang TS, Oh JK, Seward JB. Diagnosis and management of cardiac tamponade in the era of echocardiography. *Clin Cardiol*. 1999;22:446-452.
41. Spodick DH. Acute cardiac tamponade. *N Engl J Med*. 2003;349:684-690.
42. Kürkciyan I, Meron G, Sterz F, et al. Pulmonary embolism as a cause of cardiac arrest: presentation and outcome. *Arch Intern Med*. 2000;160:1529-1535.
43. Alerhand S, Sundaram T, Gottlieb M. What are the echocardiographic findings of acute right ventricular strain that suggest pulmonary embolism? *Anaesth Crit Care Pain Med*. 2021;40:100852-100853.
44. Wardi G, Blanchard D, Dittrich T, et al. Right ventricle dysfunction and echocardiographic parameters in the first 24h following resuscitation in the post-cardiac arrest patient: a retrospective cohort study. *Resuscitation*. 2016;103:71-74.
45. Aagaard R, Granfeldt A, Bøtker MT, et al. The right ventricle is dilated during resuscitation from cardiac arrest caused by hypovolemia: a porcine ultrasound study. *Crit Care Med*. 2017;45:e963-e970.
46. Aagaard R, Caap P, Hansson NC, et al. Detection of pulmonary embolism during cardiac arrest-ultrasonographic findings should be interpreted with caution. *Crit Care Med*. 2017;45:e695-e702.
47. Sørensen AH, Wemmelund KB, Møller-Helgestad OK, et al. Asphyxia causes ultrasonographic D-shaping of the left ventricle—an experimental porcine study. *Acta Anaesthesiol Scand*. 2016;60:203-212.
48. Galiè N, Humbert M, Vachiery JL, et al. 2015 ESC/ERS Guidelines for the diagnosis and treatment of pulmonary hypertension: the Joint Task Force for the Diagnosis and Treatment of Pulmonary Hypertension of the European Society of Cardiology (ESC) and the European Respiratory Society (ERS): endorsed by: Association for European Paediatric and Congenital Cardiology (AEPC), International Society for Heart and Lung Transplantation (ISHLT). *Eur Heart J*. 2016;37:67-119.
49. Augustine DX, Coates-Bradshaw LD, Willis J, et al. Echocardiographic assessment of pulmonary hypertension: a guideline protocol from the British Society of Echocardiography. *Echo Res Pract*. 2018;5:G11-G24.
50. Rudski LG, Lai WW, Afilalo J, et al. Guidelines for the echocardiographic assessment of the right heart in adults: a report from the American Society of Echocardiography endorsed by the European Association of Echocardiography, a registered branch of the European Society of Cardiology, and the Canadian Society of Echocardiography. *J Am Soc Echocardiogr*. 2010;23:685-713; quiz 786-788.
51. Budhram GR, Mader TJ, Lutfy L, et al. Left ventricular thrombus development during ventricular fibrillation and resolution during resuscitation in a swine model of sudden cardiac arrest. *Resuscitation*. 2014;85:689-693.
52. Lau V, Blaszak M, Lam J, et al. Point-of-Care Resuscitative Echocardiography Diagnosis of Intracardiac Thrombus during cardiac arrest (PREDICT Study): a retrospective, observational cohort study. *Resusc Plus*. 2022;10:100218-100219.
53. Konstantinides SV, Torbicki A, Agnelli G, et al. 2014 ESC guidelines on the diagnosis and management of acute pulmonary embolism. *Eur Heart J*. 2014;35(43):3033-3069; 3069a-3069k.

54. Lee JH, Lee SH, Yun SJ. Comparison of 2-point and 3-point-of-care ultrasound techniques for deep vein thrombosis at the emergency department: a meta-analysis. *Med (Baltim)*. 2019;98: e15791-e15791.
55. Pomero F, Dentali F, Borretta V, et al. Accuracy of emergency physician-performed ultrasonography in the diagnosis of deep-vein thrombosis: a systematic review and meta-analysis. *Thromb Haemost*. 2013;109:137-145.
56. Amaya SC, Langsam A. Ultrasound detection of ventricular fibrillation disguised as asystole. *Ann Emerg Med*. 1999;33:344-346.
57. Blaivas M, Fox JC. Outcome in cardiac arrest patients found to have cardiac standstill on the bedside emergency department echocardiogram. *Acad Emerg Med*. 2001;8:616-621.
58. Querellou E, Meyran D, Petitjean F, et al. Ventricular fibrillation diagnosed with trans-thoracic echocardiography. *Resuscitation*. 2009;80:1211-1213.
59. Limb C, Siddiqui MA. Apparent asystole: are we missing a lifesaving opportunity? *BMJ Case Rep*. 2015;2015: bcr2014208364-bcr2014208365.
60. Gaspari R, Weekes A, Adhikari S, et al. Comparison of outcomes between pulseless electrical activity by electrocardiography and pulseless myocardial activity by echocardiography in out-of-hospital cardiac arrest; secondary analysis from a large, prospective study. *Resuscitation*. 2021;169:167-172.
61. Teran F, Dean AJ, Centeno C, et al. Evaluation of out-of-hospital cardiac arrest using transesophageal echocardiography in the emergency department. *Resuscitation*. 2019;137:140-147.
62. Zengin S, Yavuz E, Al B, et al. Benefits of cardiac sonography performed by a non-expert sonographer in patients with non-traumatic cardiopulmonary arrest. *Resuscitation*. 2016;102:105-109.
63. Benjamin EJ, Virani SS, Callaway CW, et al. Heart disease and stroke Statistics-2018 update: a report from the American Heart Association. *Circulation*. 2018;137:e67-e492.
64. Brown JM. Use of echocardiography for hemodynamic monitoring. *Crit Care Med*. 2002;30:1361-1364.
65. Ciozda W, Kedan I, Kehl DW, et al. The efficacy of sonographic measurement of inferior vena cava diameter as an estimate of central venous pressure. *Cardiovasc Ultrasound*. 2016;14:33-34.
66. Bendjelid K, Romand JA, Walder B, et al. Correlation between measured inferior vena cava diameter and right atrial pressure depends on the echocardiographic method used in patients who are mechanically ventilated. *J Am Soc Echocardiogr*. 2002;15:944-949.
67. Mitaka C, Nagura T, Sakanishi N, et al. Two-dimensional echocardiographic evaluation of inferior vena cava, right ventricle, and left ventricle during positive-pressure ventilation with varying levels of positive end-expiratory pressure. *Crit Care Med*. 1989;17:205-210.
68. Jue J, Chung W, Schiller NB. Does inferior vena cava size predict right atrial pressures in patients receiving mechanical ventilation? *J Am Soc Echocardiogr*. 1992;5:613-619.
69. Gottlieb M, Holladay D, Burns KM, et al. Ultrasound for airway management: an evidence-based review for the emergency clinician. *Am J Emerg Med*. 2020;38:1007-1013.
70. Gottlieb M, Olszynski P, Atkinson P. Just the facts: point-of-care ultrasound for airway management. *CJEM*. 2021;23:277-279.
71. Tanigawa K, Takeda T, Goto E, et al. The efficacy of esophageal detector devices in verifying tracheal tube placement: a randomized cross-over study of out-of-hospital cardiac arrest patients. *Anesth Analg*. 2001;92:375-378.
72. Li J. Capnography alone is imperfect for endotracheal tube placement confirmation during emergency intubation. *J Emerg Med*. 2001;20:223-229.
73. Takeda T, Tanigawa K, Tanaka H, et al. The assessment of three methods to verify tracheal tube placement in the emergency setting. *Resuscitation*. 2003;56:153-157.
74. Zechner PM, Breitkreutz R. Ultrasound instead of capnometry for confirming tracheal tube placement in an emergency? *Resuscitation*. 2011;82:1259-1261.
75. Ornato JP, Shipley JB, Racht EM, et al. Multicenter study of a portable, hand-size, colorimetric end-tidal carbon dioxide detection device. *Ann Emerg Med*. 1992;21:518-523.
76. Gottlieb M, Holladay D, Peksa GD. Ultrasonography for the confirmation of endotracheal tube intubation: a systematic review and meta-analysis. *Ann Emerg Med*. 2018;72:627-636.
77. Gottlieb M, Holladay D, Serici A, et al. Comparison of color flow with standard ultrasound for the detection of endotracheal intubation. *Am J Emerg Med*. 2018;36:1166-1169.
78. Gottlieb M, Nakitende D, Sundaram T, et al. Comparison of Static versus Dynamic ultrasound for the Detection of Endotracheal Intubation. *West J Emerg Med*. 2018;19:412-416.
79. Gottlieb M, Holladay D, Burns K, et al. Accuracy of ultrasound for endotracheal intubation between different transducer types. *Am J Emerg Med*. 2019;37:2182-2185.
80. Gottlieb M, Holladay D, Nakitende D, et al. Variation in the accuracy of ultrasound for the detection of intubation by endotracheal tube size. *Am J Emerg Med*. 2019;37:706-709.
81. Gottlieb M, Burns K, Holladay D, et al. Impact of endotracheal tube twisting on the diagnostic accuracy of ultrasound for intubation confirmation. *Am J Emerg Med*. 2020;38:1332-1334.
82. Gottlieb M, Patel D, Jung C, et al. Comparison of saline versus air for identifying endotracheal intubation with ultrasound. *Am J Emerg Med*. 2022;58:131-134.
83. Gottlieb M, Patel D, Sundaram T. Comparison of endotracheal tube location on ultrasound accuracy, time, and confidence. *Am J Emerg Med*. 2022; S0735-6757:00550-00552.
84. Gotttlieb M, Patel D, Sundaram T. Comparison of endotracheal tube location on ultrasound accuracy, time, and confidence. *Am J Emerg Med*. 2022. https://doi.org/10.1016/j.ajem.2022.08.048. In press.
85. Heinonen J, Takki S, Tammisto T. Effect of the Trendelenburg tilt and other procedures on the position of endotracheal tubes. *Lancet*. 1969;1:850-853.
86. Tessaro MO, Salant EP, Arroyo AC, et al. Tracheal rapid ultrasound saline test (T.R.U.S.T.) for confirming correct endotracheal tube depth in children. *Resuscitation*. 2015;89:8-12.
87. Uya A, Spear D, Patel K, et al. Can novice sonographers accurately locate an endotracheal tube with a saline-filled cuff in a cadaver model? A pilot study. *Acad Emerg Med*. 2012;19:361-364.
88. Wani TM, John J, Rehman S, et al. Point-of-care ultrasound to confirm endotracheal tube cuff position in relationship to the cricoid in the pediatric population. *Paediatr Anaesth*. 2021;31:1310-1315.
89. Gottlieb M, Berzins D, Hartrich M, et al. Diagnostic accuracy of ultrasound to confirm endotracheal tube depth. *Am J Emerg Med*. 2022;62:9-13.
90. Uya A, Gautam NK, Rafique MB, et al. Point-of-care ultrasound in sternal Notch confirms depth of endotracheal tube in children. *Pediatr Crit Care Med*. 2020;21:e393-e398.
91. Lichtenstein DA, Lascols N, Prin S, et al. The "lung pulse": an early ultrasound sign of complete atelectasis. *Intensive Care Med*. 2003;29:2187-2192.
92. Alerhand S, Tsung JW. Unmasking the lung pulse for detection of endobronchial intubation. *J Ultrasound Med*. 2020;39:2105-2109.
93. Gottlieb M, Alerhand S, Long B. Point-of-care ultrasound for intubation confirmation of COVID-19 patients. *West J Emerg Med*. 2020;21:1042-1045.
94. Blaivas M, Tsung JW. Point-of-care sonographic detection of left endobronchial main stem intubation and obstruction versus endotracheal intubation. *J Ultrasound Med*. 2008;27:785-789.

95. Chan KK, Joo DA, McRae AD, et al. Chest ultrasonography versus supine chest radiography for diagnosis of pneumothorax in trauma patients in the emergency department. *Cochrane Database Syst Rev*. 2020;7:CD013031-CD013032.
96. Helland G, Gaspari R, Licciardo S, et al. Comparison of four views to single-view ultrasound protocols to identify clinically significant pneumothorax. *Acad Emerg Med*. 2016;23:1170-1175.
97. Laan DV, Vu TDN, Thiels CA, et al. Chest wall thickness and decompression failure: a systematic review and meta-analysis comparing anatomic locations in needle thoracostomy. *Injury*. 2016;47:797-804.
98. Gottlieb M, Long B. Managing spontaneous pneumothorax. *Ann Emerg Med*. Published online October 31, 2022. https://doi.org/10.1016/j.annemergmed.2022.08.447.
99. Moore C, Todd WM, O'Brien E, et al. Free fluid in Morison's pouch on bedside ultrasound predicts need for operative intervention in suspected ectopic pregnancy. *Acad Emerg Med*. 2007;14:755-758.
100. Hendrickson RG, Dean AJ, Costantino TG. A novel use of ultrasound in pulseless electrical activity: the diagnosis of an acute abdominal aortic aneurysm rupture. *J Emerg Med*. 2001;21:141-144.
101. Netherton S, Milenkovic V, Taylor M, et al. Diagnostic accuracy of eFAST in the trauma patient: a systematic review and meta-analysis. *CJEM*. 2019;21:727-738.
102. Lalande E, Burwash-Brennan T, Burns K, et al. Is point-of-care ultrasound a reliable predictor of outcome during traumatic cardiac arrest? A systematic review and meta-analysis from the SHoC investigators. *Resuscitation*. 2021;167:128-136.
103. Lalande E, Burwash-Brennan T, Burns K, et al. Is point-of-care ultrasound a reliable predictor of outcome during atraumatic, non-shockable cardiac arrest? A systematic review and meta-analysis from the SHoC investigators. *Resuscitation*. 2019;139:159-166.
104. Gaspari R, Weekes A, Adhikari S, et al. A retrospective study of pulseless electrical activity, bedside ultrasound identifies interventions during resuscitation associated with improved survival to hospital admission. A REASON Study. *Resuscitation*. 2017;120:103-107.
105. Gaspari R, Teran F, Kamilaris A, et al. Development and validation of a novel image quality rating scale for echocardiography during cardiac arrest. *Resusc Plus*. 2021;6:100097-100098.
106. Hu K, Gupta N, Teran F, et al. Variability in interpretation of cardiac standstill among physician sonographers. *Ann Emerg Med*. 2018;71:193-198.
107. Teran F, Paradis NA, Dean AJ, et al. Quantitative characterization of left ventricular function during pulseless electrical activity using echocardiography during out-of-hospital cardiac arrest. *Resuscitation*. 2021;167:233-241.
108. Ramjee V, Grossestreuer AV, Yao Y, et al. Right ventricular dysfunction after resuscitation predicts poor outcomes in cardiac arrest patients independent of left ventricular function. *Resuscitation*. 2015;96:186-191.
109. Eberle B, Dick WF, Schneider T, et al. Checking the carotid pulse check: diagnostic accuracy of first responders in patients with and without a pulse. *Resuscitation*. 1996;33:107-116.
110. Bahr J, Klingler H, Panzer W, et al. Skills of lay people in checking the carotid pulse. *Resuscitation*. 1997;35:23-26.
111. Ochoa FJ, Ramalle-Gómara E, Carpintero JM, et al. Competence of health professionals to check the carotid pulse. *Resuscitation*. 1998;37:173-175.
112. Liberman M, Lavoie A, Mulder D, et al. Cardiopulmonary resuscitation: errors made by pre-hospital emergency medical personnel. *Resuscitation*. 1999;42:47-55.
113. Deakin CD, Low JL. Accuracy of the advanced trauma life support guidelines for predicting systolic blood pressure using carotid, femoral, and radial pulses: observational study. *BMJ*. 2000;321:673-674.
114. Dick WF, Eberle B, Wisser G, et al. The carotid pulse check revisited: what if there is no pulse? *Crit Care Med*. 2000;28(suppl)N183-N185.
115. Tibballs J, Weeranatna C. The influence of time on the accuracy of healthcare personnel to diagnose paediatric cardiac arrest by pulse palpation. *Resuscitation*. 2010;81:671-675.
116. Badra K, Coutin A, Simard R, et al. The POCUS pulse check: a randomized controlled crossover study comparing pulse detection by palpation versus by point-of-care ultrasound. *Resuscitation*. 2019;139:17-23.
117. Schwartz BE, Gandhi P, Najafali D, et al. Manual Palpation vs. femoral arterial Doppler ultrasound for Comparison of Pulse Check Time During cardiopulmonary resuscitation in the emergency department: a pilot study. *J Emerg Med*. 2021;61:720-730.
118. Kang SY, Jo IJ, Lee G, et al. Point-of-care ultrasound compression of the carotid artery for pulse determination in cardiopulmonary resuscitation. *Resuscitation*. 2022; S0300-9572:00590-00591.
119. Adedipe AA, Fly DL, Schwitz SD, et al. Carotid Doppler blood flow measurement during cardiopulmonary resuscitation is feasible: a first in man study. *Resuscitation*. 2015;96:121-125.
120. Simard RD, Unger AG, Betz M, et al. The POCUS pulse check: a case series on a novel method for determining the presence of a pulse using point-of-care ultrasound. *J Emerg Med*. 2019;56:674-679.
121. Cohen AL, Li T, Becker LB, et al. Femoral artery Doppler ultrasound is more accurate than manual palpation for pulse detection in cardiac arrest. *Resuscitation*. 2022;173:156-165.
122. Sanchez S, Miller M, Asha S. Assessing the validity of two-dimensional carotid ultrasound to detect the presence and absence of a pulse. *Resuscitation*. 2020;157:67-73.
123. Smith DJ, Simard R, Chenkin J. Checking the pulse in the 21st century: interobserver reliability of carotid pulse detection by point-of-care ultrasound. *Am J Emerg Med*. 2021;45:280-283.
124. Germanoska B, Coady M, Ng S, et al. The reliability of carotid ultrasound in determining the return of pulsatile flow: a pilot study. *Ultrasound*. 2018;26:118-126.
125. Fair J, Mallin M, Mallemat H, et al. Transesophageal echocardiography: guidelines for point-of-care applications in cardiac arrest resuscitation. *Ann Emerg Med*. 2018;71:201-207.
126. Fair J, Mallin MP, Adler A, et al. Transesophageal echocardiography during cardiopulmonary resuscitation is associated with shorter compression pauses compared with transthoracic echocardiography. *Ann Emerg Med*. 2019;73:610-616.
127. Blaivas M. Transesophageal echocardiography during cardiopulmonary arrest in the emergency department. *Resuscitation*. 2008;78:135-140.
128. Arntfield R, Pace J, Hewak M, et al. Focused transesophageal echocardiography by emergency physicians is feasible and clinically influential: observational results from a novel ultrasound program. *J Emerg Med*. 2016;50:286-294.
129. Memtsoudis SG, Rosenberger P, Loffler M, et al. The usefulness of transesophageal echocardiography during intraoperative cardiac arrest in noncardiac surgery. *Anesth Analg*. 2006;102:1653-1657.
130. Varriale P, Maldonado JM. Echocardiographic observations during in hospital cardiopulmonary resuscitation. *Crit Care Med*. 1997;25:1717-1720.
131. Comess KA, DeRook FA, Russell ML, et al. The incidence of pulmonary embolism in unexplained sudden cardiac arrest with pulseless electrical activity. *Am J Med*. 2000;109:351-356.
132. Shillcutt SK, Markin NW, Montzingo CR, et al. Use of rapid "rescue" perioperative echocardiography to improve outcomes after hemodynamic instability in noncardiac surgical patients. *J Cardiothorac Vasc Anesth*. 2012;26:362-370.

133. Lin T, Chen Y, Lu C, Wang M. Use of transoesophageal echocardiography during cardiac arrest in patients undergoing elective non-cardiac surgery. *Br J Anaesth*. 2006;96:167-170.
134. Hilberath JN, Burrage PS, Shernan SK, et al. Rescue transoesophageal echocardiography for refractory haemodynamic instability during transvenous lead extraction. *Eur Heart J Cardiovasc Imaging*. 2014;15:926-932.
135. Jung WJ, Cha KC, Kim YW, et al. Intra-arrest transoesophageal echocardiographic findings and resuscitation outcomes. *Resuscitation*. 2020;154:31-37.
136. van der Wouw PA, Koster RW, Delemarre BJ, et al. Diagnostic accuracy of transesophageal echocardiography during cardiopulmonary resuscitation. *J Am Coll Cardiol*. 1997;30:780-783.
137. Hwang SO, Zhao PG, Choi HJ, et al. Compression of the left ventricular outflow tract during cardiopulmonary resuscitation. *Acad Emerg Med*. 2009;16:928-933.
138. Catena E, Ottolina D, Fossali T, et al. Association between left ventricular outflow tract opening and successful resuscitation after cardiac arrest. *Resuscitation*. 2019;138:8-14.
139. Giraud R, Siegenthaler N, Schussler O, et al. The LUCAS 2 chest compression device is not always efficient: an echographic confirmation. *Ann Emerg Med*. 2015;65:23-26.
140. Fair J, Tonna J, Ockerse P, et al. Emergency physician-performed transesophageal echocardiography for extracorporeal life support vascular cannula placement. *Am J Emerg Med*. 2016;34:1637-1639.
141. Teran F, Burns KM, Narasimhan M, et al. Critical care transesophageal echocardiography in patients during the COVID-19 pandemic. *J Am Soc Echocardiogr*. 2020;33:1040-1047.
142. Lerner RP, Haaland A, Lin J. Temporary transvenous pacer placement under transesophageal echocardiogram guidance in the emergency department. *Am J Emerg Med*. 2020;38. 1044.e3-1044.e4.
143. Arntfield RT, Millington SJ, Wu E. An elderly woman that presents with absent vital signs. *Chest*. 2014;146:e156-e159.
144. Hussein L, Rehman MA, Jelic T, et al. Transoesophageal echocardiography in cardiac arrest: a systematic review. *Resuscitation*. 2021;168:167-175.
145. Arntfield R, Pace J, McLeod S, et al. Focused transesophageal echocardiography for emergency physicians-description and results from simulation training of a structured four-view examination. *Crit Ultrasound J*. 2015;7:27-28.
146. Byars DV, Tozer J, Joyce JM, et al. Emergency physician-performed transesophageal echocardiography in simulated cardiac arrest. *West J Emerg Med*. 2017;18:830-834.
147. Nazerian P, De Stefano G, Albano G, et al. Transesophageal echocardiography (TEE) in cardiac arrest: results of a hands-on training for a simplified TEE protocol. *Ultrasound J*. 2020;12:41-42.
148. Reardon RF, Chinn E, Plummer D, et al. Feasibility, utility, and safety of fully incorporating transesophageal echocardiography into emergency medicine practice. *Acad Emerg Med*. 2022;29:334-343.
149. Daniel WG, Erbel R, Kasper W, et al. Safety of transesophageal echocardiography. A multicenter survey of 10,419 examinations. *Circulation*. 1991;83:817-821.
150. Kallmeyer IJ, Collard CD, Fox JA, et al. The safety of intraoperative transesophageal echocardiography: a case series of 7200 cardiac surgical patients. *Anesth Analg*. 2001;92:1126-1130.
151. Gardner KF, Clattenburg EJ, Wroe P, et al. The Cardiac Arrest Sonographic Assessment (CASA) exam – A standardized approach to the use of ultrasound in PEA. *Am J Emerg Med*. 2018;36:729-731.
152. Hernandez C, Shuler K, Hannan H, et al. C.A.U.S.E.: Cardiac arrest ultra-sound exam—a better approach to managing patients in primary non-arrhythmogenic cardiac arrest. *Resuscitation*. 2008;76:198-206.
153. Chu SE, Chang CJ, Chen HA, et al. Core Ultrasound in REsuscitation (CURE): a novel protocol for ultrasound-assistant life support via application of both transesophageal and transthoracic ultrasound. *Resuscitation*. 2022;173:1-3.
154. Breitkreutz R, Price S, Steiger HV, et al. Focused echocardiographic evaluation in life support and peri-resuscitation of emergency patients: a prospective trial. *Resuscitation*. 2010;81:1527-1533.
155. Breitkreutz R, Walcher F, Seeger FH. Focused echocardiographic evaluation in resuscitation management: concept of an advanced life support-conformed algorithm. *Crit Care Med*. 2007;35(suppl):S150-S161.
156. Testa A, Cibinel GA, Portale G, et al. The proposal of an integrated ultrasonographic approach into the ALS algorithm for cardiac arrest: the PEA protocol. *Eur Rev Med Pharmacol Sci*. 2010;14:77-88.
157. Ávila-Reyes D, Acevedo-Cardona AO, Gómez-González JF, et al. Point-of-care ultrasound in cardiorespiratory arrest (POCUS-CA): narrative review article. *Ultrasound J*. 2021;13:46.
158. Niendorff DF, Rassias AJ, Palac R, et al. Rapid cardiac ultrasound of inpatients suffering PEA arrest performed by nonexpert sonographers. *Resuscitation*. 2005;67:81-87.
159. Chua MT, Chan GW, Kuan WS. Reversible causes in cardiovascular collapse at the emergency department using ultrasonography (REVIVE-US). *Ann Acad Med Singap*. 2017;46:310-316.
160. Lichtenstein DA. How can the use of lung ultrasound in cardiac arrest make ultrasound a holistic discipline. The example of the SESAME-protocol. *Med Ultrason*. 2014;16:252-255.
161. Lichtenstein D, Malbrain MLNG. Critical care ultrasound in cardiac arrest. Technological requirements for performing the SESAME-protocol—a holistic approach. *Anaesthesiol Intensive Ther*. 2015;47:471-481.
162. Atkinson P, Bowra J, Milne J, et al. International Federation for Emergency Medicine Consensus Statement: sonography in hypotension and cardiac arrest (SHoC): an international consensus on the use of point of care ultrasound for undifferentiated hypotension and during cardiac arrest. *CJEM*. 2017;19:459-470.
163. Atkinson PR, Beckett N, French J, et al. Does point-of-care ultrasound use impact resuscitation length, rates of intervention, and clinical outcomes during cardiac arrest? A study from the sonography in hypotension and cardiac arrest in the emergency department (SHoC-ED) investigators. *Cureus*. 2019;11:e4456-e4457.
164. Beckett N, Atkinson P, Fraser J, et al. Do combined ultrasound and electrocardiogram-rhythm findings predict survival in emergency department cardiac arrest patients? the second sonography in hypotension and cardiac arrest in the emergency department (SHoC-ED2) study. *CJEM*. 2019;21:739-743.
165. Lien WC, Liu YP, Chong KM, et al. A novel US-CAB protocol for ultrasonographic evaluation during cardiopulmonary resuscitation. *Resuscitation*. 2017;115:e1-e2.
166. Lien WC, Hsu SH, Chong KM, et al. US-CAB protocol for ultrasonographic evaluation during cardiopulmonary resuscitation: validation and potential impact. *Resuscitation*. 2018;127:125-131.

Did you know?

Podcasts are available for almost every article in *Annals*.

Visit http://www.annemergmed.com/content/podcast to find out more.