American Journal of Emergency Medicine 58 (2022) 159–174

Contents lists available at ScienceDirect

American Journal of Emergency Medicine

journal homepage: www.elsevier.com/locate/ajem

Pericardial tamponade: A comprehensive emergency medicine and echocardiography review

Stephen Alerhand, MD [a,*], Robert James Adrian, MD [a], Brit Long, MD [b], Jacob Avila, MD [c]

[a] Department of Emergency Medicine, Rutgers New Jersey Medical School, 150 Bergen Street, Newark, NJ 07103, USA
[b] Department of Emergency Medicine, Brooke Army Medical Center, Fort Sam Houston, TX 78234, USA
[c] Department of Emergency Medicine, UHS Southern California Medical Education Consortium, Temecula, CA 92592, USA

ARTICLE INFO

Article history:
Received 7 March 2022
Accepted 3 May 2022

Keywords:
Pericardial tamponade
Cardiac tamponade
Pericardial effusion
Pericardiocentesis
Pericardial drainage
Echocardiography
Point-of-care ultrasound
POCUS
Pulsus paradoxus
Electrical alternans
Ventricular interdependence
Pericardial decompression syndrome

ABSTRACT

Introduction: Pericardial tamponade requires timely diagnosis and management. It carries a high mortality rate.
Objective: This review incorporates available evidence to clarify misconceptions regarding the clinical presentation, while providing an in-depth expert guide on bedside echocardiography. It also details the decision-making strategy for emergency management including pericardiocentesis, along with pre- and peri-procedural pearls and pitfalls.
Discussion: Pericardial effusions causing tamponade arise from diverse etiologies across acute and sub-acute time courses. The most frequently reported symptom is dyspnea. The classically taught Beck's triad (which includes hypotension) does not appear commonly. Echocardiographic findings include: a pericardial effusion (larger size associated with tamponade), diastolic right ventricular collapse (specific), systolic right atrial collapse (sensitive), a plethoric non-collapsible inferior vena cava (sensitive), and sonographic pulsus paradoxus. Emergent pericardiocentesis is warranted by hemodynamic instability, impending deterioration, or cardiac arrest. Emergent surgical indications include type A aortic dissection causing hemopericardium, ventricular free wall rupture after acute myocardial infarction, severe chest trauma, and iatrogenic hemopericardium when bleeding cannot be controlled percutaneously. Pre-procedure management includes blood products for patients with traumatic hemopericardium; gentle intravenous fluids to hypotensive, hypovolemic patients with consideration for vasoactive medications; treatment of anticoagulation, coagulopathies, and anemia. Positive-pressure ventilation and intravenous sedation can lower cardiac output and should be avoided if possible. Optimal location for echocardiography-guided pericardiocentesis is the largest, shallowest fluid pocket with no intervening vital structures. Patient positioning to prevent hypoxia and liberal amounts of local anesthesia can facilitate patients remaining still. Safe needle guidance and confirmation of catheter placement is achieved using low-depth sonographic views, injection of agitated saline, and evaluation of initial aspirate for hemorrhage. Pericardial fluid should be drained slowly to avoid pericardial decompression syndrome.
Conclusion: An understanding of the pathophysiology, clinical presentation, echocardiographic findings, and time-sensitive management of pericardial tamponade is essential for emergency physicians.
© 2022 Elsevier Inc. All rights reserved.

1. Introduction

Under normal circumstances, physiologic serous fluid exists within the pericardial sac and acts as lubrication for the heart. A pericardial effusion refers to when this fluid exceeds 15-50 mL [1]. Pericardial tamponade refers to hemodynamic instability and clinical symptoms owing directly to that effusion. This occurs when the pressure exerted on one or more cardiac chambers by the pericardial effusion (i.e. the intrapericardial pressure) exceeds the pressures within the cardiac chambers (i.e. the intracardiac pressure), leading to obstruction of normal chamber filling.

The development of tamponade physiology is dependent on the rate of accumulation of the pericardial fluid and the pericardial compliance [2]. For example, with an acute effusion, the pericardial sac has not had time to develop compensatory compliance, so a rapid increase in intrapericardial pressure leads to tamponade physiology. The pericardial stretch limit can be reached quickly, even with as little as 50 mL [3,4]. In contrast, with a chronic effusion, the pericardial sac is able to develop compliance over time, so much larger fluid volumes (up to two liters) [2,5] can be tolerated before development of tamponade physiology requiring drainage. As the pericardial compliance eventually approaches its limit, small additional increases in volume cause relatively larger increases in intrapericardial pressure (Fig. 1, top-center).

* Corresponding author at: 150 Bergen Street, Newark, NJ 07103, USA.
E-mail address: Stephen.Alerhand@gmail.com (S. Alerhand).

https://doi.org/10.1016/j.ajem.2022.05.001
0735-6757/© 2022 Elsevier Inc. All rights reserved.

Downloaded for Anonymous User (n/a) at The University of Arizona from ClinicalKey.com by Elsevier on April 10, 2023. For personal use only. No other uses without permission. Copyright ©2023. Elsevier Inc. All rights reserved.

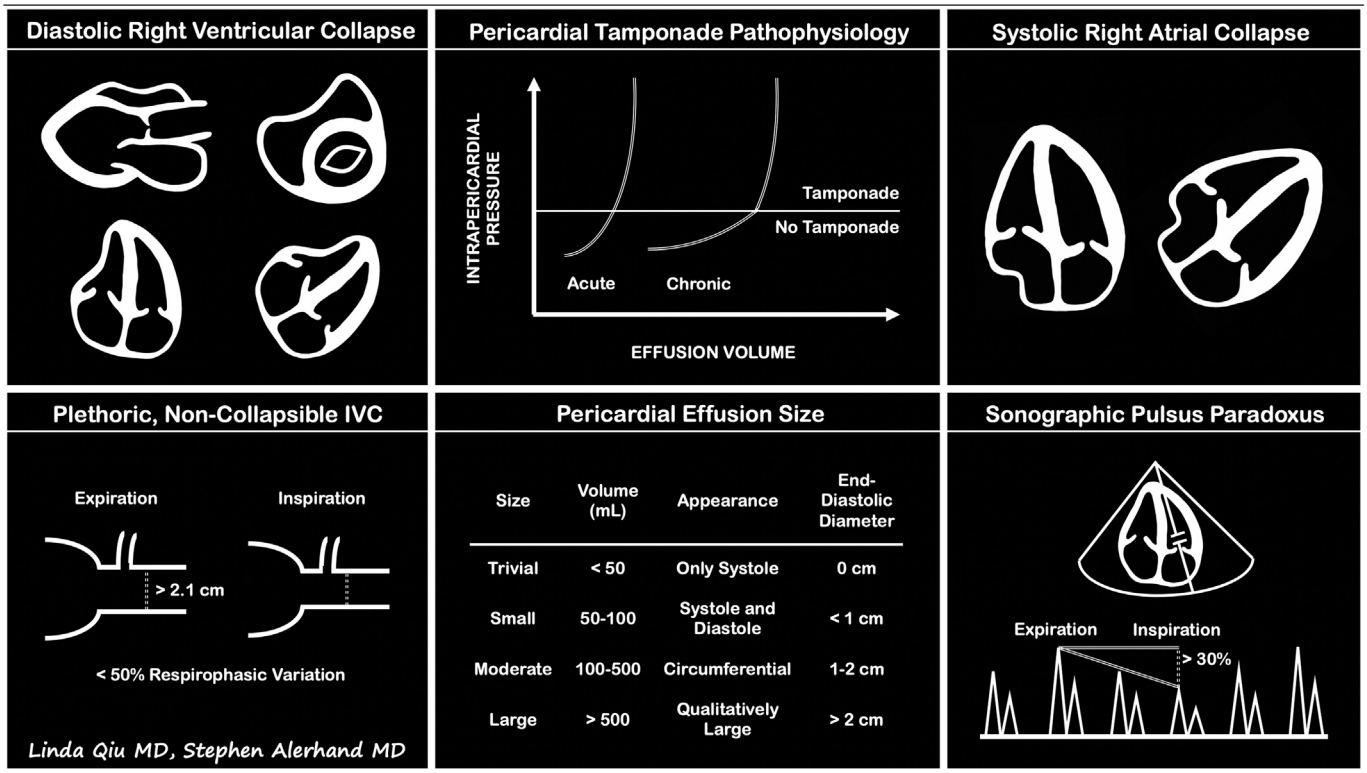

Fig. 1. Infographic delineating the pathophysiology and echocardiographic findings of pericardial tamponade (echocardiography graphic design by Linda Qiu MD).

As pulmonary vascular resistance is lower than systemic vascular resistance, the right-sided cardiac chambers normally operate at lower pressures compared to the left-sided chambers. In pericardial tamponade, when the right atrium (RA) and right ventricle (RV) collapse during ventricular systole and diastole, respectively (i.e. when they are at their lowest pressures), there is decreased preload to the right side of the heart. The decrease in right ventricular stroke volume transmits along its circuit to the left side of the heart, ultimately leading to decreased cardiac output.

The spectrum of disease in pericardial tamponade ranges from slight elevations of intrapericardial pressure causing only subtle hemodynamic effects to severe hemodynamic compromise from obstructive shock [6]. If left untreated, this pathophysiology can lead to cardiac arrest and death.

2. Methods

The authors searched PubMed and Google Scholar for articles using the title keywords "cardiac tamponade" OR "pericardial tamponade." The search was conducted from the databases' inception to February 1, 2022. The literature search was restricted to studies published in English, with a focus on the emergency medicine, critical care, and cardiology literature. Supporting citations of included articles were also reviewed. Authors decided which studies to include by consensus. When available, guidelines and systematic reviews and meta-analyses (SRMAs) were preferentially selected. These were followed sequentially by randomized controlled trials, prospective studies, retrospective studies, case reports, and other narrative reviews.

3. Discussion

3.1. Demographics and outcomes

Pericardial tamponade is a rare but life-threatening condition. In a national inpatient sample database of 216 million admissions from 2008-2014, 0.05% of patients (5 cases per 10,000) were diagnosed with pericardial tamponade [7]. Emergency physicians must be aware of the various potential etiologies for a pericardial effusion causing tamponade and the patients who are at risk (Table 1) [5,8-21]. A meta-analysis consisting of 17,022 patients with pulmonary, infectious, cardiac, renal, or neoplastic disease found that 19.5% of patients had a pericardial effusion [22]. In a retrospective review of 322 patients with moderate-large effusions (> 1 cm end-diastolic diameter) (see Section 3.4.1), the etiology arose from an already known medical condition in 60% of cases [11]. Similarly, in another retrospective review of 153 emergency department (ED) patients with point-of-care ultrasound (POCUS) scans showing a pericardial effusion, 62.5% carried historical features suggesting the presence of an effusion [23].

Some of these effusions, especially the larger ones, eventually lead to tamponade physiology. A retrospective study of 187 hospitalized patients diagnosed with a pericardial effusion found that moderate-large effusions (circumferential; >1 cm end-diastolic diameter) were more likely to develop tamponade (based on the authors' hemodynamic criteria) or have a drainage procedure than small effusions (73% vs. 5%) [24]. These events usually occurred on the same day that the effusion was diagnosed. For patients with end-stage renal disease on hemodialysis, a larger effusion size is also predictive of tamponade and development of hemodynamic compromise [25-31]. In patients with large idiopathic chronic pericardial effusions, four separate studies of 100, 45, 28, and 22 patients found that 8 (8%), 0 (0%), 8 (29%), and 2 (9.1%) of patients developed tamponade at median follow-up of 4 years, 10 months, 7 years, and 2 years, respectively [32-35]. In the two largest studies, the effusion regressed in 39 (39%) and 2 (4.5%) of patients, respectively [32,33].

In general, short-term survival depends mostly upon early diagnosis and relief of tamponade, whereas long-term survival depends on the underlying primary illness [36]. In-hospital mortality rates for pericardial tamponade can be subdivided by etiology (Table 2). In a study of 78 patients with acute myocardial infarction and free wall rupture (i.e. the tamponade etiology with the highest in-hospital mortality rate),

Downloaded for Anonymous User (n/a) at The University of Arizona from ClinicalKey.com by Elsevier on April 10, 2023. For personal use only. No other uses without permission. Copyright ©2023. Elsevier Inc. All rights reserved.

Table 1
Etiologies of pericardial effusions causing tamponade.

Etiology	Percentage of Cases
Malignancy	15-65%
Idiopathic	4-37%
Infectious/inflammatory	4-31%
Iatrogenic	3-35%
Metabolic	1-33%
Bleeding/anticoagulation	2-31%
Autoimmune/vasculitis	1-14%
Acute myocardial infarction	1-12%
Decompensated thyroid disease	1-10%
Aortic dissection	1-4%
Traumatic	1-2%

the majority of patients (83.3%) presented already in cardiac arrest and died in 100% of cases [37]. For those patients presenting with a sudden change in clinical condition, moderate-massive effusion (by the authors' unspecified criteria), and pericardiocentesis showing bloody fluid (9.0%), the mortality rate was 85.7% and typically occurred within 4.5 hours. These patients may benefit from surgery within that time period. Patients with normal vital signs, moderate-massive effusion, and pericardiocentesis showing bloody fluid (7.7%) were found to have a 16.7% mortality rate. In the long-term, pericardial tamponade stemming from a malignant effusion (i.e. the most common effusion etiology of tamponade) carries a 1-year mortality rate between 68-89% [10,14,15,17]. The cause of death in these patients is generally from the end-stage neoplastic disease, not necessarily the effusion itself [5,13].

3.2. Emergency department presentation

3.2.1. Symptoms

Though patients will be unable to provide a history if obtunded or in cardiac arrest, a variety of presenting complaints have been reported, most commonly dyspnea (Table 3) [21,40-46]. Clinical symptoms may appear less often in patients with low-flow tamponade, which is generally attributed to hypovolemia [47]. Nevertheless, symptoms will vary depending on the etiology of the effusion itself, and there is no "classic" presentation.

The classic teaching for the diagnosis of pericardial tamponade had involved Beck's triad. The initial data came from two cases published in 1935: an acute triad was described as "falling arterial pressure, rising venous pressure and a small quiet heart", whereas the chronic triad was described as "ascites, high venous pressure and a quiet heart" [48]. However, a subsequent 2007 SRMA reviewed studies of patients with known tamponade or who were referred for pericardiocentesis of a known effusion [40]. Hypotension, jugular venous distention, and muffled heart sounds occurred in only 14-35%, 53-88%, and 24-34% of cases, respectively. In an ED-based study, the sensitivities of hypotension, jugular venous distention, and muffled heart sounds for a pericardial effusion causing tamponade (based on electronic medical record diagnosis) were 37.5%, 12.5% and 37.5%, respectively [23]. The sensitivity of one element of Beck's triad to diagnose pericardial tamponade was 50%, and no patients with tamponade had all three elements.

Table 2
In-hospital mortality rates for various etiologies of pericardial tamponade.

Etiology	In-Hospital Mortality Rate
Acute myocardial infarction	70-100% [13,17,37-39]
Aortic dissection	65% [9]
Bleeding/anticoagulation	40% [17]
Malignancy	16% [17]
Iatrogenic	10% [17]
Infectious/inflammatory	8% [17]

Table 3
Symptoms in pericardial tamponade.

Symptom	Percentage of Cases
Dyspnea	66-90%
Chest pain	12-74%
Fever	7-70%
Abdominal pain	12-61%
Orthopnea	23-51%
Lethargy/weakness	3-14%
Syncope	3-6%
Palpitations	3%
Headache	2%

Although pericardial tamponade represents an acutely dangerous condition, patients (especially those with malignant effusions) may present with symptoms that have been ongoing for up to one week [17,49,50]. The variations and subtleties in the patient presentation can lead to early failure in making the diagnosis. Moreover, the pericardial effusion may be found by an echocardiogram performed for reasons other than a clinical suspicion for tamponade [49]. Nevertheless, the reported frequency of non-specific symptoms and physical examination findings prior to making the diagnosis has decreased over time, which one study's authors attribute to an improvement in cardiovascular imaging and a high index of suspicion [49].

3.2.2. Vital signs

3.2.2.1. Blood pressure. Hypotension is traditionally taught as being present in patients with pericardial tamponade. However, a systolic blood pressure (SBP) < 100 mmHg only occurs in 14-35% of patients with non-traumatic pericardial tamponade [19,42-44]. In a retrospective review of 342 patients who underwent pericardiocentesis for a clinically significant pericardial effusion, only 9.6% had SBP ≤ 90 mmHg [45].

An assessment of six studies comprising 235 patients with pericardial tamponade found that SBP ranged between 127-144 mmHg [51]. In an ED-based study of 205 patients diagnosed with tamponade who underwent pericardiocentesis within 24 hours of ED presentation (excluding trauma patients and those who received cardiopulmonary resuscitation), the mean SBP was 106 mmHg [21]. In the ED-based study of 153 patients with a pericardial effusion, the sensitivity of hypotension for tamponade (based on electronic medical record diagnosis) was 37.5% [23]. Another retrospective study of 46 patients who underwent percutaneous pericardiocentesis found that hypotension was 24% sensitive and 83% specific for tamponade (based on the presence of diastolic chamber collapse) [42].

Hypotension is especially uncommon when the effusion develops over days to weeks [40,41,51,52]. Increased sympathetic tone can maintain SBP even as cardiac output decreases [53]. High levels of circulating catecholamines in response to hemodynamic stress can even produce hypertensive tamponade [52,54]. The previously mentioned assessment of six studies reported that 27-43% of patients with pericardial tamponade had SBP ≥ 140 mmHg [51].

3.2.2.2. Heart rate. Since cardiac compression by a pericardial effusion limits diastolic filling and stroke volume, a compensatory tachycardia develops in an attempt to maintain cardiac output. The 2007 SRMA found that a heart rate > 100 beats per minute occurred in 65-88% of patients with pericardial tamponade [40]. In the ED-based study of 205 patients diagnosed with tamponade who underwent pericardiocentesis within 24 hours of ED presentation, the mean heart rate was 100 beats per minute [21]. In the ED-based study of 153 patients with a pericardial effusion, a heart rate > 100 beats per minute was 69% sensitive for a pericardial effusion causing tamponade (based on electronic medical record diagnosis) [23]. Lastly, the retrospective study of 46 patients who underwent percutaneous pericardiocentesis found that a heart rate > 100 beats per minute was 88% sensitive and 67% specific for

Downloaded for Anonymous User (n/a) at The University of Arizona from ClinicalKey.com by Elsevier on April 10, 2023. For personal use only. No other uses without permission. Copyright ©2023. Elsevier Inc. All rights reserved.

tamponade (based on the presence of diastolic chamber collapse) [42]. Of note, tachycardia may be blunted by beta-blockade or conduction system disease.

3.2.2.3. Respiratory rate. Only one study included in the 2007 SRMA reported statistics for respiratory rate. It found that tachypnea was present in 80% of patients with pericardial tamponade [40]. In the ED-based study of 205 patients diagnosed with tamponade who underwent pericardiocentesis within 24 hours of ED presentation, the mean respiratory rate was 21 breaths per minute [21]. Of note, tachypnea may not be present late in the disease course if there is respiratory muscle fatigue.

3.2.3. Physical examination

Physical examination findings in patients with pericardial tamponade vary widely and are poorly predictive (Table 4). The assessment and interpretation of some findings (e.g. jugular venous distention) can differ even amongst experienced physicians [55,56].

3.3. Emergency department evaluation

3.3.1. Electrocardiogram

Electrocardiogram (ECG) findings vary in pericardial tamponade, with tachycardia being the most common finding (Table 5).

3.3.2. Chest radiography

The 2007 SRMA included four studies in which an enlarged cardiac contour was present on chest radiograph in 68-100% of cases with pericardial tamponade [19,42,44,57]. In patients with hemodynamic instability or concerning symptoms for whom transport poses a risk, only a portable chest radiograph will be feasible.

3.4. Point-of-care echocardiography

Suspicion for pericardial tamponade is raised by clinical evaluation, with confirmation by bedside echocardiography [59]. Guidelines from the American Heart Association, American College of Cardiology, American Society of Echocardiography (ASE), and European Society of Cardiology (ESC) posit echocardiography as the first-level diagnostic tool in the evaluation of suspected pericardial disease [60,61]. There are certain echocardiographic findings suggesting tamponade physiology of which emergency physicians should be aware (Fig. 1) [59]. Since these findings are reflective of hemodynamic compromise, their presence even in hemodynamically stable patients can help identify those who are at risk for disease progression. Of note, the predictive values of these echocardiographic findings for tamponade are heavily influenced by the disease prevalence in a given population [62]. Therefore, they must be interpreted in the context of the patient's pretest probability based on clinical history, symptoms, vital signs, and physical examination.

In the ED-based study of 205 patients diagnosed with tamponade who underwent pericardiocentesis within 24 hours of ED presentation, patients who underwent the procedure within 12 hours had had a shorter time to POCUS than those who did so within 12-24 hours (48 vs. 78 minutes, respectively) [21]. Three other separate retrospective reviews have evaluated patients with clinically significant pericardial effusions (non-iatrogenic, non-traumatic, and penetrating cardiac injury proven at operation or autopsy, respectively) [45,63,64]. They all also found that use of POCUS was associated with lower time-to-diagnosis and time-to-pericardiocentesis. In the first study (n = 263), there was no statistical difference in hemodynamic profile between the POCUS and departmental echocardiography groups [45]. In the second study (n = 73), the POCUS group had a lower average SBP than the other-imaging group (117.6 mmHg vs. 134.6 mmHg), but this difference would not be clinically significant on its own to raise concern for tamponade [63]. Studies assessing POCUS in penetrating cardiac injury have also shown improved outcomes such as survival rate and neurologic outcome (as per the Glasgow Outcome Score) [64-68].

Table 5
Electrocardiogram findings in patients with pericardial tamponade.

Electrocardiogram Findings	Percentage of Cases (%)
Tachycardia	47-88% [40,41,45]
Low-voltage QRS complexes	22-56% [19,42-45,57]
ST-segment elevation	18-30% [19,57]
Electrical alternans	3-21% [19,43,45]
PR-segment depression	18% [43]
Atrial arrhythmias	0-9% [19,43,58]

[40] is an SRMA that obtained statistics for heart rate based on physical examination (i.e. a tachycardic patient would presumably show tachycardia on ECG).

3.4.1. Pericardial effusion

ASE recommendations and an American College of Emergency Physicians (ACEP) position statement support the use of emergency physician-performed POCUS to visualize a pericardial effusion (of only 15-35 mL) in both the medical and trauma settings [1,69]. In a prospective ED-based study of 515 patients with high-risk medical and traumatic criteria for the diagnosis of pericardial effusion, POCUS scans by trained emergency physicians were 96% sensitive, 98% specific, and 97.5% accurate for the presence of an effusion against the reference standard of one cardiologist's review [70]. In another prospective observational study that included 67 cardiac POCUS scans (8 with an effusion), emergency physicians with no prior POCUS experience who underwent a 4-hour training program performed scans with 88% sensitivity and 98% specificity for pericardial effusion, also compared to the reference interpretation of one blinded cardiologist [71].

A pericardial effusion should be classified by its hemodynamic impact, size, distribution, onset, and composition (Table 6). ASE and European Association of Cardiovascular Imaging (EACVI) guidelines recommend estimating effusion size by the end-diastolic diameter between the visceral and parietal pericardium (i.e. the parietal separation distance) (Table 7) [1,72]. Seeing an evenly distributed effusion from multiple sonographic views increases the predictive value of this size estimation [1]. In the ED-based study of 205 patients diagnosed with tamponade who underwent pericardiocentesis within 24 hours of ED presentation, 58% of effusions were large, 35% were moderate, and

Table 4
Physical Examination Test Characteristics in Patients with Pericardial Effusions Causing Tamponade.

Physical Examination Finding	Percentage of Cases (%)	Sensitivity (%)	Specificity (%)
Elevated jugular venous pressure	41-88 [42-45]	13-88 [23,42]	83 [42]
Muffled heart sounds	3-34 [19,43]	24-38 [23,42]	100 [42]
Pulsus paradoxus	36-98 [19,43,44,45,57,58]	80-98 [42, 57]	40-100 [42, 57]

–[19,43,44,57,58] were described in an SRMA [40]. To determine the presence or absence of tamponade, three studies based their designation upon the clinical and hemodynamic response to pericardiocentesis, one study upon both clinical findings and a pericardial effusion diagnosed by echocardiography, and one study upon echocardiographic findings alone.
–[23] determined the presence of tamponade based on electronic medical record diagnosis.
–[42] determined the presence of tamponade based on diastolic chamber collapse.
-[45] evaluated patients with symptomatic pericardial effusions. Echocardiography found that 90% were circumferential, 67% had 2 cm end-diastolic diameter between the visceral and parietal pericardium, 64% had systolic right atrial collapse, 58% had diastolic right ventricular collapse, and 29% had sonographic pulsus paradoxus.

Downloaded for Anonymous User (n/a) at The University of Arizona from ClinicalKey.com by Elsevier on April 10, 2023. For personal use only. No other uses without permission. Copyright ©2023. Elsevier Inc. All rights reserved.

Table 6
Classification model for pericardial effusions.

Hemodynamic Impact	Size	Distribution	Onset	Composition
Hemodynamically stable	Trivial	Localized adjacent to specific chamber(s)	Acute	Blood
Hemodynamically unstable	Small	Circumferential	Subacute	Transudate
	Moderate		Chronic	Exudate
	Large			Air
				Gas

7% were small (based on a board-certified cardiologist's report) [21]. Interestingly, in the retrospective review of 342 patients who underwent pericardiocentesis for a clinically significant pericardial effusion, larger effusions (> 2 cm end-diastolic diameter) were found more often from a non-procedural etiology than from an iatrogenic and procedural etiology (78% vs. 30%) [45].

Due to the time-sensitive management and potentially suboptimal sonographic views in often-distressed patients with pericardial tamponade, a simple and more practical size categorization can also be determined qualitatively (Fig. 2) (Video 1) (Table 7) [1-3,59,73,74]. For determining the presence, size, and distribution of a pericardial effusion, it is important to acquire multiple cardiac views. An effusion may appear in one cardiac view but not in another, and what can appear as a small effusion in one view could actually appear large in another, and vice versa (Video 2). Pericardial fluid generally appears first posteriorly to the left ventricle (LV), moves apically and anteriorly as the fluid volume increases, and finally progresses laterally and posteriorly to the left atrium (LA) [75]. Compared to simple serous fluid that appears anechoic, hemorrhagic or purulent contents may appear more echogenic [76]. Of note, the pulmonary expansion associated with deep inspiration in dyspneic patients will decrease the amount of cardiac tissue lying close to the chest [77], as well as cause posterior displacement and rotation of the heart [78]. Whereas the parasternal views thus appear less pronounced during inspiration, downward movement of the diaphragm improves access to the subxiphoid views [77].

Caution is needed to distinguish a pericardial fat pad from a pericardial effusion (Fig. 3) (Video 3) [59]. The former will generally have a "stippled" appearance and be located in the anterior atrioventricular groove, best visualized in the parasternal long-axis (PLAX) and subxiphoid long-axis (SXLA) views [79]. In contrast, an effusion (usually anechoic) will typically collect in the most dependent pericardial location. Moreover, a pericardial fat pad adheres to the myocardium and thus moves in synchrony with the heart throughout the cardiac cycle [79]. Conversely, an effusion will alternatingly appear smaller and larger as the adjacent cardiac chamber expands and contracts within the pericardium whose space they share.

Another masquerade of a pericardial effusion is a left-sided pleural effusion [59] (Fig. 4a) (Video 4a). In the PLAX view, a pericardial effusion will appear anterior to the descending aorta, whereas a pleural effusion will appear posterior to it [80]. Additionally, whereas a pericardial effusion may appear circumferentially around the heart, a pleural effusion will not cross the midline. As confirmation, the left lung base should also be assessed for the presence of the pleural effusion (Fig. 4b) (Video 4b). Thirdly, in the SXLA view, abdominal ascites may mimic a pericardial effusion, but they can be differentiated by their locations outside and within the pericardium, respectively (Fig. 5) (Video 5). Acquiring other abdominal views of ascites can further point to that diagnosis. Lastly, cardiac tumors can appear as echo-free spaces along the epicardium [81]. Similar to a pericardial fat pad, these tumors will move in concert with the myocardium throughout the cardiac cycle.

3.4.2. Diastolic right ventricular collapse

When the intrapericardial pressure exceeds the right ventricular intracardiac pressure, the RV will collapse. Intrapericardial pressure (P) is proportional to pericardial fluid volume (V) multiplied by the stiffness of the pericardial sac ($\Delta P/\Delta V$) [59]. In early tamponade, the RV might only collapse during expiration, when positive intrathoracic pressure decreases preload to the right side of the heart (i.e. with resultant decreased intracardiac pressure). Even with disease progression, collapse of the RV may occur over a shorter duration during inspiration (i.e. negative intrathoracic pressure, increased venous return, and increased intracardiac pressure) than during expiration. In general, the longer the duration of right ventricular collapse, the more severe the tamponade [82,83]. The outflow region of the RV generally compresses earlier than does the basal portion.

This finding has been shown to be 48-60% sensitive and 75-90% specific for pericardial tamponade, though the determination of what constitutes tamponade has varied between studies [57,84-88]. In the ED-based study of 205 patients diagnosed with tamponade who underwent pericardiocentesis within 24 hours of ED presentation, diastolic right ventricular collapse was found in 85% of patients [21]. In the 342 patients who underwent pericardiocentesis for a clinically significant pericardial effusion, right ventricular collapse was found more often from a non-procedural etiology than from an iatrogenic and procedural etiology (62% vs. 33%) [45]. Moreover, in the retrospective study of 187 hospitalized patients diagnosed with a pericardial effusion, 64% of patients having a moderate-large effusion (circumferential; >1 cm end-diastolic diameter) showed diastolic right ventricular collapse compared to only 4% in small effusions (seen only posteriorly) [24].

It is critical to determine the timing of right ventricular collapse in the cardiac cycle. Whereas right ventricular free wall contraction would be normal if occurring during systole (i.e. when the atrioventricular valves are closed), its collapse during diastole (i.e. when the atrioventricular valves are open) suggests tamponade. This assessment is best performed in the apical 4-chamber (A4C) and SXLA views that provide optimal simultaneous visualization of the atrioventricular valves and entire right ventricular free wall (Fig. 6) (Video 7). The PLAX view, as well as the parasternal short-axis (PSAX) and subxiphoid short-axis (SXSA) views (particularly at the aortic valve level), visualize mostly the outflow region.

Unfortunately, patients with pericardial tamponade often present with tachycardia [23,40,42], making it difficult to determine if the atrioventricular valve opening and right ventricular free wall collapse are occurring simultaneously. The easy solution is to use the ultrasound cine loop to cycle between consecutive still frames from a frozen image or saved 6-second clip. Furthermore, in the A4C and SXLA views, the tricuspid valve (TV) and right ventricular free wall are located close together and can usually be visualized simultaneously. Similar proximity relationships exist between the PSAX and SXSA views (which only visualize a portion of the right ventricular free wall) and the mitral valve (MV). Alternatively, in the PLAX view, the MV and right ventricular

Table 7
Quantitative and qualitative size categorization of pericardial effusions.

Size	Estimated Volume	Appearance	End-Diastolic Diameter Between Visceral and Parietal Pericardium
Trivial	< 50 mL	Only in systole	0 cm
Small	50-100 mL	Systole and diastole	< 1 cm
Moderate	100-500 mL	Circumferential	1-2 cm
Large	> 500 mL	Qualitatively large	> 2 cm

Downloaded for Anonymous User (n/a) at The University of Arizona from ClinicalKey.com by Elsevier on April 10, 2023. For personal use only. No other uses without permission. Copyright ©2023. Elsevier Inc. All rights reserved.

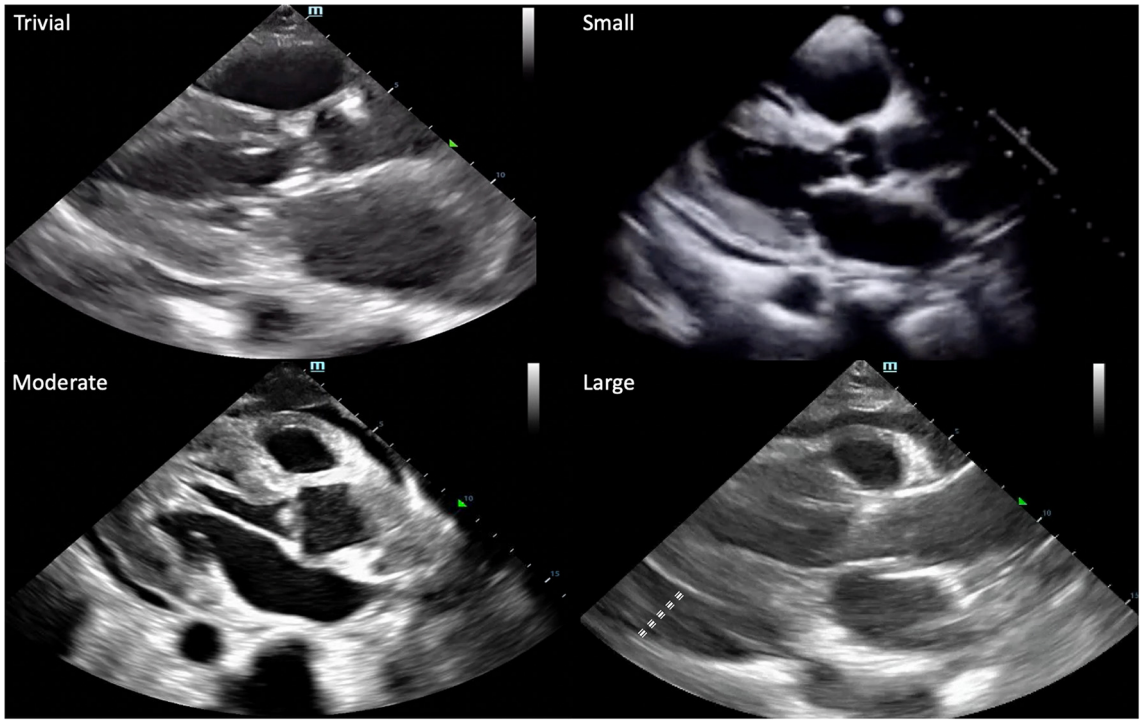

Fig. 2. A trivial, small, moderate, and large pericardial effusion in the parasternal long-axis view. For the large effusion, a dotted line delineates the end-diastolic diameter between the visceral and parietal pericardium. Using the baseline scale along the right side of the image as reference, this distance qualitatively appears to be > 2 cm.

outflow tract (RVOT) are located further apart. A helpful strategy for this view entails using M-mode due to its higher temporal resolution, with the beam directed through the center of the RVOT free wall and the tip of the anterior MV leaflet (Fig. 7). The movement of these two structures will be depicted on the y-axis over time (i.e. the x-axis), allowing determination of whether the RVOT's collapse is truly occurring during diastole.

The RV will be less likely to demonstrate diastolic collapse (and thus, tamponade physiology) in the presence of a higher baseline intrapericardial pressure (Video 6). This would be the case for cor pulmonale and pulmonary hypertension (PH) (in whom 30% of patients develop a pericardial effusion [89,90]), severe left ventricular failure, or other etiologies of right ventricular hypertrophy [58,82,83,91-96]. Alternatively, right ventricular collapse will occur more readily if the chamber's intracardiac pressures are lower, such as with hypovolemia [83,97,98].

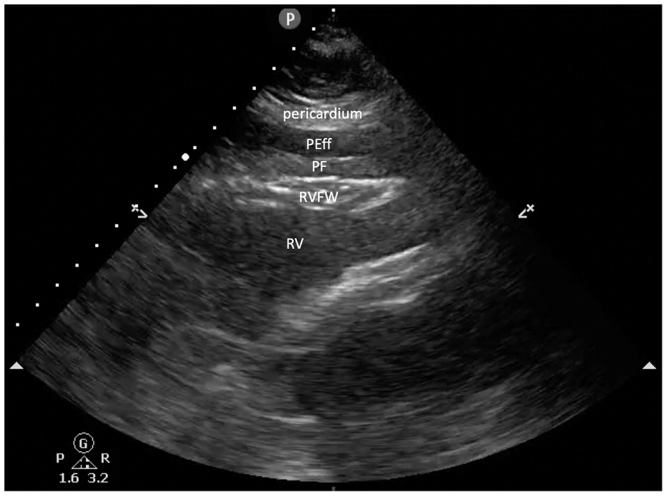

Fig. 3. A pericardial effusion and pericardial fat pad in the subxiphoid long-axis view (PEff = pericardial effusion, PF = pericardial fat pad, RVFW = right ventricular free wall, RV = right ventricle).

3.4.3. Systolic right atrial collapse

When the intrapericardial pressure exceeds the right atrial intracardiac pressure, the thin-walled RA will collapse. The right atrial pressure has the lowest pressure during systole than does any other chamber of the heart during systole or diastole. Therefore, its collapse is the earliest echocardiographic sign of tamponade [99]. Though the determination of what constituted tamponade varied between studies, this finding has been shown to be 50% sensitive for tamponade early in the disease process, but up to 100% sensitive with its progression [84,85,100,101]. Its specificity ranges from 33-100% [84,85,100-102]. These values trend higher when the duration of right atrial collapse lasts > ⅓ of the cardiac cycle [57,101,103,104]. Otherwise, collapse during < ⅓ of the cardiac cycle may simply reflect normal atrial contraction in diastole [85,101].

In the ED-based study of 205 patients diagnosed with tamponade who underwent pericardiocentesis within 24 hours of ED presentation, systolic right atrial collapse was found in 70% of patients [21]. In the 342 patients who underwent pericardiocentesis for a clinically significant pericardial effusion, right atrial collapse was found more often with non-procedural than iatrogenic and procedure-related effusions (71% vs. 41%) [45]. Moreover, in the retrospective study of 187 hospitalized patients diagnosed with a pericardial effusion, systolic right atrial collapse was found in 86% of patients having moderate-large effusions (circumferential; >1 cm end-diastolic diameter) compared to only 10% with small effusions (seen only posteriorly) [24].

Systolic right atrial collapse is best assessed in the A4C and SXLA views that provide optimal visualization of the TV and entire right atrial free wall (the PSAX and SXSA views at the aortic valve level visualize less of the free wall) (Image 8) (Video 8). Use of an offline software that provided field-by-field analysis to determine a quantitative right atrial inversion time index (i.e. number of video fields showing right

Downloaded for Anonymous User (n/a) at The University of Arizona from ClinicalKey.com by Elsevier on April 10, 2023. For personal use only. No other uses without permission. Copyright ©2023. Elsevier Inc. All rights reserved.

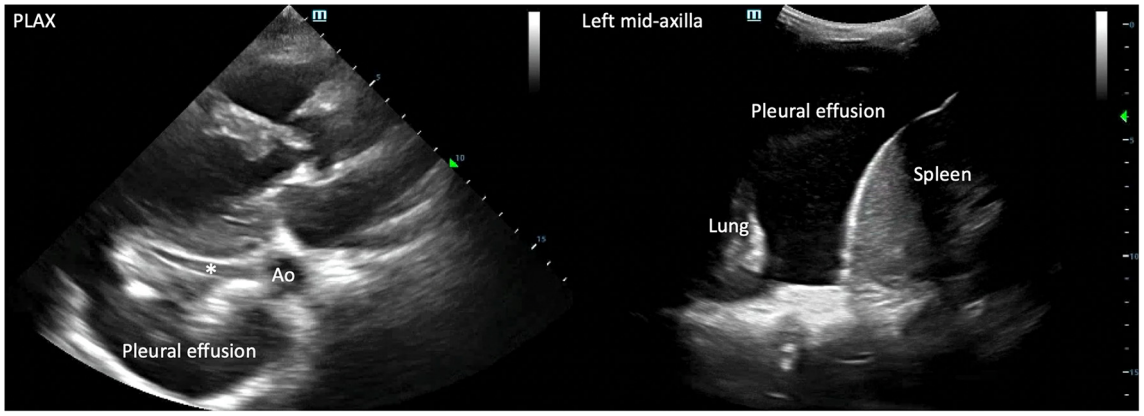

Fig. 4. PLAX) A small pericardial and a left-sided pleural effusion in the parasternal long-axis view (* = pericardial effusion, Ao = descending aorta). Left mid-axilla) A left-sided pleural effusion at the mid-axillary lung base. Rather than being filled with air and subject to sonographic artifacts, the lung tissue is actually visualized in this patient due to compressive atelectasis.

atrial collapse divided by the total number of video fields per cardiac cycle) > 0.34 was shown to improve specificity and predictive value for tamponade [101]. A similar albeit less precise evaluation can conceivably be derived on standard ultrasound machines using the ultrasound cine loop.

Compared to their left-sided counterparts, the RA and RV will collapse more readily from elevated intrapericardial pressure due to their lower baseline intracardiac pressures (3-5 mmHg and 15-25 mmHg, respectively). The lack of any right-sided chamber collapse carries a 90% negative predictive value for tamponade [85]. Some exceptions include infectious and/or loculated pericardial effusions [105-108], post-surgical complications [109-112] leading to a compressive pericardial blood clot [113], and large left-sided pleural effusions [114-118]. For instance, a loculated effusion or blood clot adjacent only to the LV would lead to the LV's collapse, thereby decreasing preload and resultant cardiac output without any right-sided heart compression. In the 342 patients who underwent pericardiocentesis for a clinically significant pericardial effusion, a regional effusion was found more often with iatrogenic and procedure-related compared to non-procedural effusions (16% vs. 2%) [45]. Post-surgical regional tamponade may occur early (within 24 hours, due to surgical bleeding or cardiopulmonary bypass-induced coagulopathy) or late (up to 5-7 days after cardiac surgery due to excessive mediastinal drainage or post-pericardiotomy syndrome) [1]. Nevertheless, a retrospective survey of 4,561 postoperative patients found that only 48 (1%) had moderate-large effusions (by unspecified criteria), with 36 of those causing tamponade [119].

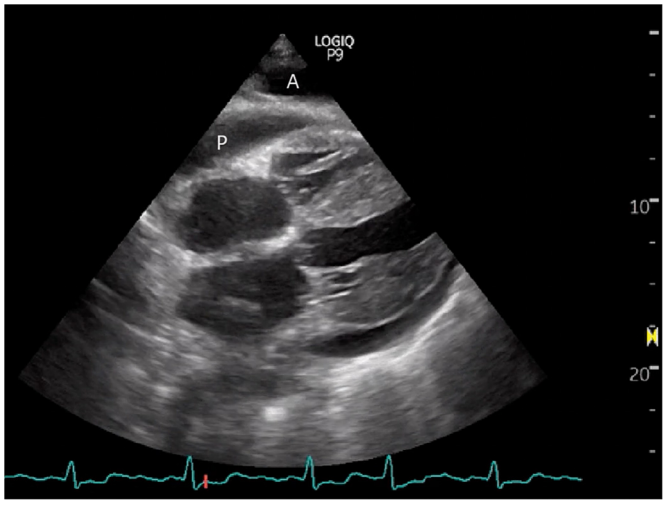

Fig. 5. Both ascites (denoted "A") and a circumferential pericardial effusion (the anterior portion denoted "P") visualized within the same subxiphoid long-axis view. The ascites lies outside the hyperechoic pericardium, whereas the effusion lies within it (adapted with permission from Abhilash Koratala MD, NephroPOCUS.com).

3.4.4. Plethoric and non-collapsible inferior vena cava

When compressed by the elevated intrapericardial pressure from a pericardial effusion, the RA is unable to accommodate incoming preload from the inferior vena cava (IVC). Hence, analogous to the sensitivity of systolic right atrial collapse, a plethoric IVC with minimal respirophasic variation is 95-97% sensitive for tamponade, though the definition of tamponade has varied between studies [1,84,93,120,121]. Exceptions include patients with low-pressure tamponade, who do not have significant venous congestion yet still benefit from pericardial aspiration [122]. In the ED-based study of 205 patients diagnosed with tamponade who underwent pericardiocentesis within 24 hours of ED presentation, a plethoric IVC was found in 70% of patients [21]. In the retrospective study of 187 hospitalized patients diagnosed with a pericardial effusion, a plethoric IVC with blunted respirophasic variation was present in 75% of patients having a moderate-large effusion (circumferential; >1 cm end-diastolic diameter), compared to only 32% when the effusion was small (seen only posteriorly) [24].

The long-axis of the IVC can be visualized inferior to the xiphoid process in the sagittal plane (Fig. 9) (Video 9). The diameter is evaluated just proximal to the hepatic vein inflow that lies between 0.5-3.0 cm from the IVC-RA junction [123]. The use of M-mode is not recommended, because inadvertently placing the beam obliquely to the long-axis of the IVC (versus perpendicularly) will overestimate IVC diameter and underestimate its collapsibility. The opposite will occur (i.e. an underestimated diameter and overestimated collapsibility) if the transducer is not placed (or does not remain) along the IVC's long-axis during the evaluation [123].

ASE guidelines define a plethoric IVC as having diameter > 2.1 cm with < 50% respirophasic variation [1,123]. However, in the time-sensitive context of evaluating symptomatic patients, a qualitative binary assessment of plethoric and non-collapsible versus thin or collapsible is sufficient [59].

3.4.5. Respirophasic variation in mitral and tricuspid inflow velocities as a surrogate for pulsus paradoxus

Under normal circumstances, spontaneous inspiration and associated chest cavity expansion draw air into the lungs due to the negative intrathoracic pressure. Increased lung oxygen content leads to a decrease in pulmonary vascular resistance, thereby facilitating increased

Downloaded for Anonymous User (n/a) at The University of Arizona from ClinicalKey.com by Elsevier on April 10, 2023. For personal use only. No other uses without permission. Copyright ©2023. Elsevier Inc. All rights reserved.

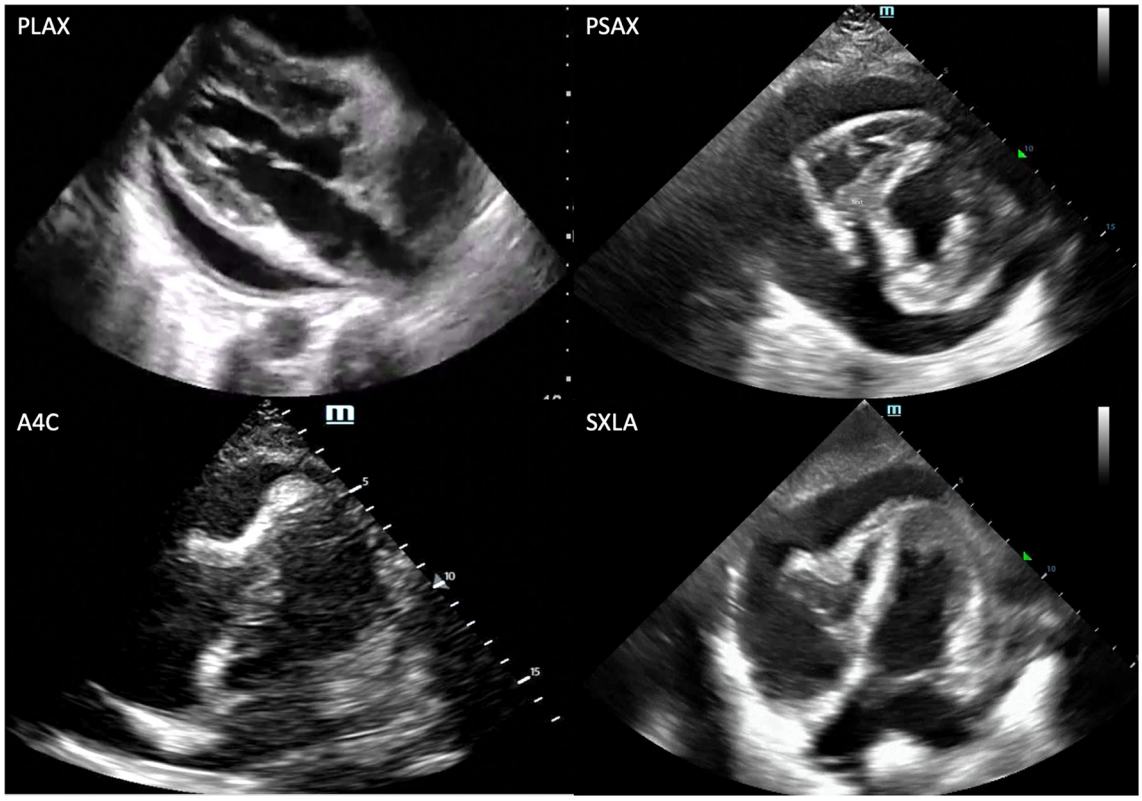

Fig. 6. Diastolic right ventricular collapse from large pericardial effusions in the parasternal long-axis, parasternal short-axis, apical 4-chamber, and subxiphoid long-axis views.

blood flow through the right side of the heart to the pulmonary arterial system. As the two ventricles occupy the same space within the pericardial sac, an increase in filling of the RV is normally associated with a minimal (< 5%) decrease in filling of the LV [92].

With pericardial tamponade from an evenly distributed effusion, an elevation in intrapericardial pressure (generally > 15 mmHg when severe) leads to equalization of the right and left ventricular end-diastolic pressures (i.e. within 5 mmHg) [1]. Since the ventricles now also compete with the effusion for space within the pericardial sac, the effects of ventricular interdependence are more pronounced. An increase or decrease in the diastolic volume of one ventricle will have the opposite effect on the volume of the other ventricle. Accordingly, with the increased right-sided cardiac filling associated with inspiration, the RV cannot fully expand due to the effusion, and there will be further bulging of the interventricular septum towards the LV than normal. As a result, there will be decreased blood flow through the left side of the heart, with a resultant drop in stroke volume. This manifests as the abnormally large decrease in inspiratory SBP > 10 mmHg seen with pulsus paradoxus.

An echocardiographic surrogate for the changes in blood flow through the left and right sides of the heart is the measurement of

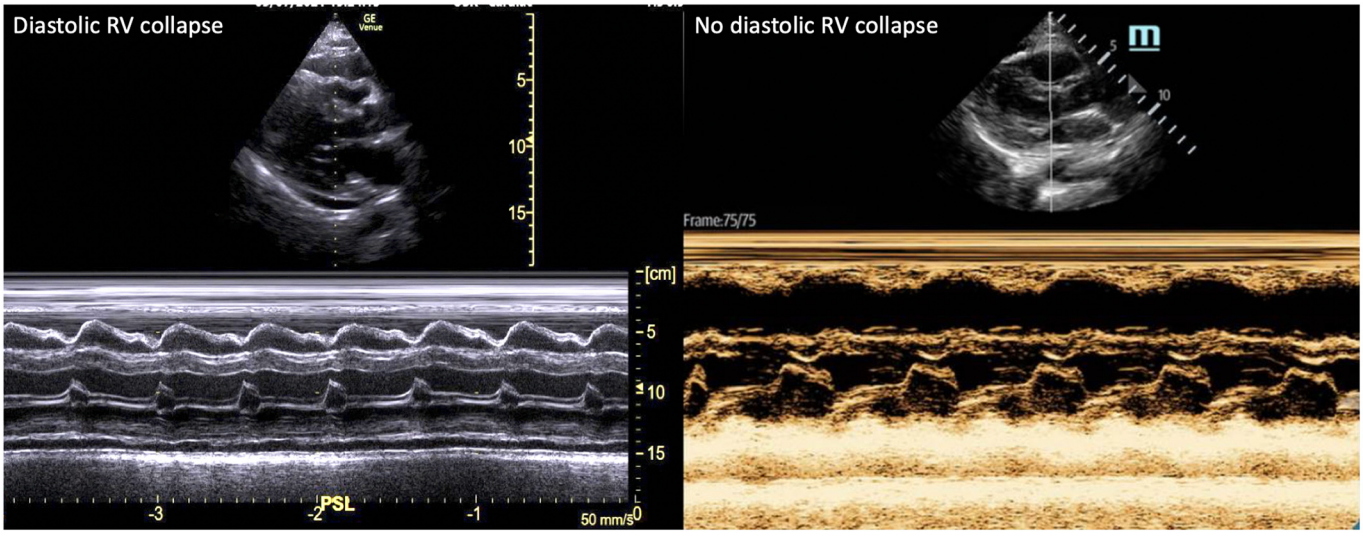

Fig. 7. A) M-mode of diastolic right ventricular collapse in the parasternal long-axis view. Note how the inward movement of the right ventricular outflow tract free wall corresponds with the timing of the mitral valve opening (i.e. diastole). B) No diastolic right ventricular collapse. Note how the right ventricular outflow tract free wall does not bow inwards when the anterior mitral valve leaflet is open.

Downloaded for Anonymous User (n/a) at The University of Arizona from ClinicalKey.com by Elsevier on April 10, 2023. For personal use only. No other uses without permission. Copyright ©2023. Elsevier Inc. All rights reserved.

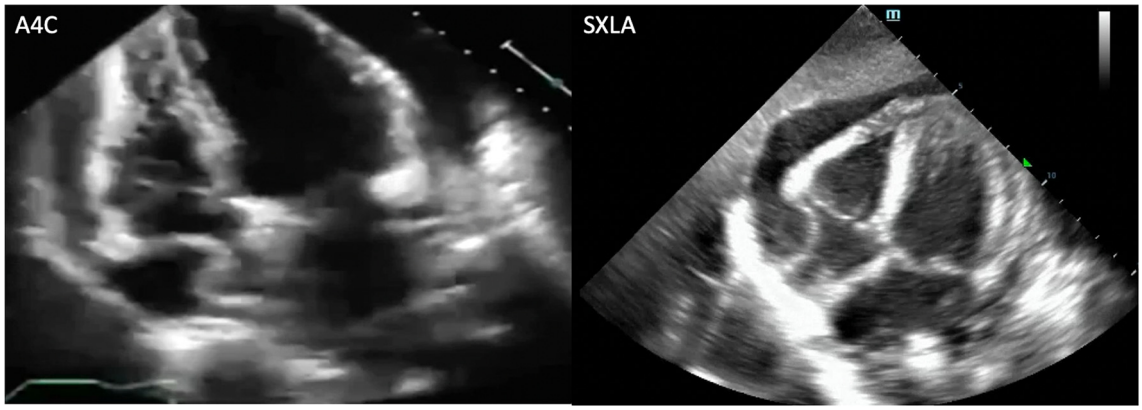

Fig. 8. Systolic right atrial collapse from large pericardial effusions in the apical 4-chamber and subxiphoid long-axis views. Note the invagination of the right atrial free wall when the tricuspid valve is closed (i.e. during systole).

blood flow velocities through the MV and TV, respectively [124,125]. These velocities, along with their variation over several heartbeats between inspiration and expiration, can be obtained using pulsed wave Doppler in the A4C view (Fig. 10). In this orientation, blood through the atrioventricular valves will flow roughly in the same direction as the sound waves emitted from the transducer, providing the largest obtainable Doppler shift (i.e. Doppler shift $F_D \propto \cos(\theta)$; $\cos(0^\circ) = 1$).

Under normal circumstances, the peak respirophasic variation in E-wave mitral inflow velocity is approximately 5% [125]. In spontaneously breathing patients with pericardial tamponade, there will be an approximately > 30% inspiratory decrease in blood flow velocity through the MV and > 60% inspiratory increase through the TV [1,46,59,61,85,124,126,127]. The magnitude of this respiratory variation is not predictive of pericardial pressure or severity of hemodynamic compromise [128]. This finding may also appear with marked dyspnea, severe chronic obstructive pulmonary disease, and pulmonary embolism [129]. In the ED-based study of 205 patients diagnosed with tamponade who underwent pericardiocentesis within 24 hours of ED presentation, exaggerated mitral inflow velocity variability was found in 78% of patients [21]. In the 342 patients who underwent pericardiocentesis for a clinically significant pericardial effusion, respirophasic transvalvular flow variation was found more often with non-procedural than with iatrogenic and procedure-related effusions (33% vs. 15%) [45]. Of note, for patients receiving positive-pressure ventilation, sonographic pulsus paradoxus is not as useful for determining whether an effusion is causing tamponade. In an experimental study of subjects receiving positive-pressure ventilation, respirophasic variation in MV inflow velocity was greater than normal (36%), decreased with a pericardial effusion (29%), and decreased even further with tamponade (16%) [130]. Since the left ventricular filling gradient in pericardial tamponade is already compromised by cardiac compression, the respiratory variations in pleural and pericardial pressures due to positive-pressure ventilation have minimal effect.

3.5. Emergency department management

The ultimate management of pericardial tamponade is drainage of the effusion. Just as even a small amount of additional fluid can push the intrapericardial pressure above the intracardiac pressure (i.e. causing tamponade), drainage of a small amount of fluid can relieve tamponade due to the steep pericardial pressure-volume relationship (Fig. 1, top-center). After drainage, the cardiac chambers can fully expand, allow incoming preload, and thereby produce sufficient stroke volume and cardiac output. The procedure's timing (i.e. emergent, urgent, or elective) and technique (i.e. percutaneous pericardiocentesis or surgical drainage) depend on certain considerations.

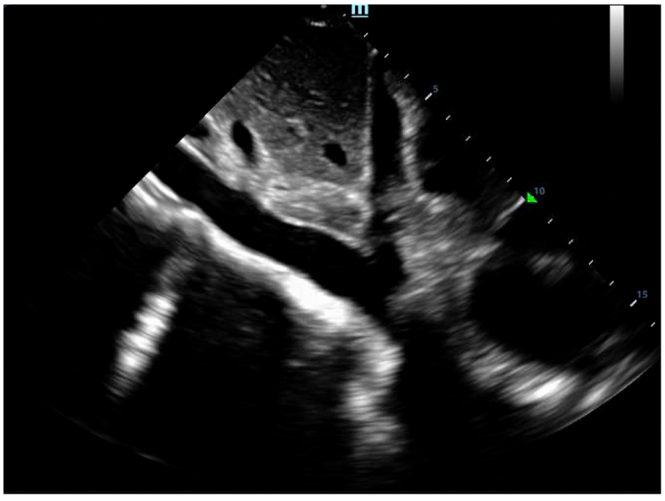

Fig. 9. A plethoric and non-collapsible inferior vena cava visualized draining into the right atrium in the subxiphoid long-axis plane.

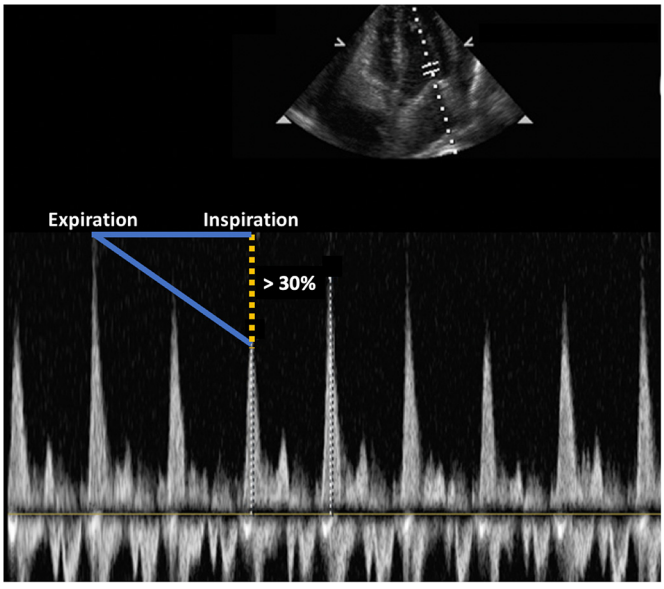

Fig. 10. Exaggerated respirophasic variation of mitral valve inflow velocity as a surrogate for pulsus paradoxus.

Downloaded for Anonymous User (n/a) at The University of Arizona from ClinicalKey.com by Elsevier on April 10, 2023. For personal use only. No other uses without permission. Copyright ©2023. Elsevier Inc. All rights reserved.

Table 8
Indications for emergent [8,127,131,132] and urgent (while admitted) [8,132-140] pericardiocentesis.

Emergent	Urgent
Hemodynamic shock	Purulent, tuberculous, or neoplastic effusion
Impending cardiac arrest	Human immunodeficiency virus or other immunosuppression
Cardiac arrest	Loculated effusion not amenable to percutaneous drainage
Rapidly deteriorating patients with iatrogenic hemopericardium	Symptomatic despite medical treatment

3.5.1. To drain or not to drain

For a patient with a pericardial effusion, the emergency physician must decide whether the effusion requires drainage, and if so, whether the procedure must be performed emergently versus urgently (within 12-48 hours while admitted) (Table 8). These decisions depend on the clinical presentation, changes in hemodynamic status over time, risk-benefit ratio of the procedure, and echocardiographic findings [8]. In brief, the emergency physician must perform the pericardiocentesis in the ED when any delay could lead to the patient's hemodynamic collapse and death.

For those patients with tamponade but not in hemodynamic shock, the ESC published a triage strategy in 2014 that provides a numerical score corresponding to the risk and likelihood of developing obstructive shock and hemodynamic compromise [8]. First, the etiology is assessed for its association with large effusions (e.g. malignancy). Second, the clinical presentation is assessed for highly symptomatic patients (e.g. orthopnea without rales) who are acutely worsening, and with concerning vital signs or physical examination findings. Third, bedside echocardiography is assessed for a circumferential pericardial effusion and other sonographic signs of tamponade. Suggestive ECG (e.g. low voltage) and chest radiograph (e.g. cardiomegaly) findings fall under this step as well. Higher scores call for immediate drainage, whereas lower scores allow delay for up to 12-48 hours. If the hospital has limited experience with pericardial drainage, transfer to a specialized institution is indicated so long as the patient is clinically stable [8].

Regardless of this numerical score, the ESC advocates that certain indications warrant urgent surgical management (Table 9) [8,141]. For patients with aortic dissection or myocardial rupture, pericardiocentesis may cause an increase in SBP from a temporary rise in cardiac output. This can lead to worsening of the dissection with potential aortic rupture and recurrent pericardial bleeding, respectively [142-145]. However, if surgical management is not promptly available for an aortic dissection or the patient is unlikely to survive transfer to the operating room, controlled percutaneous drainage of very small amounts of hemopericardium (raising the SBP to the lowest acceptable level ~ 90 mmHg) can be attempted as a stabilizing measure [146-150].

In hemodynamically stable patients with pericardial effusions, another author group previously developed a stepwise pathway-based algorithm in 2011 for quantifying the need for pericardial drainage [151]. They used the CHASER mnemonic for entry into this pathway: Chest pain, Hypotension or Arrest, Shortness of breath, Echocardiographic or other imaging finding of pericardial effusion, and Right-predominant heart failure. Echocardiographic parameters included pericardial effusion etiology, size, and findings suggestive of hemodynamic compromise. The following year, the same author group retrospectively evaluated this tool in hospitalized patients with moderate-large effusions (≥ 1 cm end-diastolic diameter) and no hemodynamic compromise on admission [152]. The pericardial effusion scoring index obtained from the initial presentation (i.e. initial medical contact leading to evaluation for pericardial effusion) showed a high accuracy in identifying patients who required pericardial drainage at a mean follow-up of 2.5 days later.

For patients with moderate-large effusions (≥ 1 cm end-diastolic diameter), another author group in 2021 retrospectively derived and internally validated a simplified tool to predict the risk of pericardial drainage or death attributed to tamponade within 24 hours [46]. Variables incorporated into a numerical score included SBP < 100 mmHg, pericardial effusion diameter, diastolic right ventricular collapse, and > 25% respirophasic variation of the mitral inflow velocity. The need for drainage within 24 hours was risk-stratified as low (8.1%), intermediate (63.8%), or high (93.7%), respectively.

Though emergent drainage of a large pericardial effusion without hemodynamic compromise is not indicated in the ED, these patients nonetheless warrant coordination with consulting services (i.e. cardiology) for conservative management and monitoring over time, or perhaps elective drainage [132,134,135,153].

3.5.2. Contraindications to pericardiocentesis

There are no absolute contraindications to pericardiocentesis in the setting of pericardial tamponade causing hemodynamic shock. However, several relative contraindications exist (Table 10) [8,154]. Nevertheless, two such examples—thrombocytopenia (< 50,000 10^3 cells/μL) and coagulopathy (INR ≥ 1.5)—did not demonstrate an association with major bleeding complications in a retrospective review of 1,196 echocardiography-guided pericardiocentesis procedures performed by experienced cardiologists [155]. Moreover, platelet transfusion in thrombocytopenic patients does not appear to modify the risks of pericardial drainage [156,157].

3.5.3. Management considerations preceding emergent pericardiocentesis

First, in the brief time interval between diagnosis and emergent drainage, hemodynamics and end-organ perfusion should be optimized. For a patient with penetrating injury to the chest causing cardiac rupture and hemorrhagic shock, blood products should be administered emergently [158]. For patients with non-traumatic tamponade, administration of 250-500 mL intravenous fluids (IVF) over 10 minutes should be considered in dehydrated hypovolemic patients with an SBP < 100 mmHg [141,159-163]. In these patients, volume expansion may lead to a rise (albeit modest) in arterial pressure and cardiac output. An increase in cardiac output from receiving IVF has also been predicted by a resting heart rate > 109 beats per minute, but not by a larger pericardial effusion size, presence of right atrial or ventricular collapse, or raised jugular venous pressure [159,160].

As a caution against liberal IVF administration, an increase in arterial pressure could be offset by an increase in left ventricular end-diastolic pressure causing pulmonary edema [160,164]. Moreover, in a reflection of increased ventricular interdependence occurring with pericardial

Table 9
Indications for urgent surgical mnagement regardless of pericardial effusion etiology, patient presentation, and echocardiographic findings

Indications for Urgent Surgical Management of Pericardial Tamponade
Type A aortic dissection causing hemopericardium
Ventricular free wall rupture after acute myocardial infarction
Severe chest trauma
Iatrogenic hemopericardium when bleeding cannot be controlled percutaneously

Table 10
Relative contraindications to pericardiocentesis

Relative Contraindications to Pericardiocentesis
Uncorrected coagulopathy
Ongoing anticoagulant therapy with INR > 1.5
Thrombocytopenia < 50,000 cells/μL
Posterior pericardial effusion
Loculated pericardial effusion
Effusion responding to anti-inflammatory treatment

Downloaded for Anonymous User (n/a) at The University of Arizona from ClinicalKey.com by Elsevier on April 10, 2023. For personal use only. No other uses without permission. Copyright ©2023. Elsevier Inc. All rights reserved.

tamponade, volume expansion of the right-sided chambers may lead to compression of the left-sided chambers with a corresponding drop in cardiac output [161]. Therefore, volume expansion above 500 mL is not recommended unless the patient clearly remains hypovolemic.

Furthermore, due to a decreased stroke volume in pericardial tamponade, cardiac output becomes dependent on compensatory tachycardia. If the heart rate fails to increase appropriately, the use of inotropy for inducing tachycardia can be considered [165]. Experimental studies have examined the potential role of various inotropes and vasopressors in tamponade [166,167], with some supporting the use of the β-adrenergic agent isoproterenol due to its positive inotropy (via β_1 receptors), peripheral vasodilation to reduce systemic vascular resistance (via β_2 receptors), and positive chronotropic effects [168-171]. Unfortunately, isoproterenol may not be readily available in all ED's. A more widely available and better option may be low-dose epinephrine (0.01-0.5 mcg/kg/min), which works more specifically as an inotrope (via β_1 receptors) with some vasoconstrictive effects (via α_1 receptors), which minimizes potential hypotension.

Second, anticoagulation, coagulopathies, and anemia must be treated as quickly as possible, preferably prior to pericardial drainage [8]. Third, elevated blood pressure readings should not be treated aggressively. A medication-induced decrease in blood pressure, along with relief of the sympathetic surge following pericardial drainage, may together contribute to significant hypotension and hemodynamic compromise [51,172].

Fourth, it may be tempting to place a dyspneic patient on positive-pressure non-invasive ventilation. However, when the associated increase in intrathoracic pressure decreases preload to the right heart, it also decreases intracardiac pressures and renders those chambers more susceptible to collapse from the elevated intrapericardial pressure. This leads to a further decrease in cardiac output than would be expected from just positive-pressure ventilation. The positive end-expiratory pressure (PEEP) also compresses the heart, vena cavae, and pulmonary vasculature, which leads to reduced filling of both right- and left-sided cardiac chambers [167,173]. Furthermore, endotracheal intubation and invasive ventilation pose even greater risks, as the cardiovascular-depressing induction and sedation agents contribute to hypotension and decreased cardiac output [174]. Therefore, maintenance of spontaneous ventilation is recommended [173,175,176], with dissociative agents such as ketamine of potential use for performing the pericardiocentesis [177]. During this time, hypercarbia should be avoided, as it increases pericardial pressure and (through respiratory acidosis) decreases cardiac performance [178].

If non-invasive or invasive ventilation cannot be avoided, drainage of pericardial fluid should ideally be performed beforehand [173,179]. Otherwise, initiation of positive-pressure ventilation should at least be delayed until pericardial drainage is imminent [173,175,176,179]. For the intubation itself, an awake intubation (i.e. airway topicalization followed by gently-induced sedation and analgesia) can be used to avoid the deleterious effects on cardiac output by the typical dosing for induction and sedation agents [176,179]. Once intubated, higher respiratory rates (and therefore smaller tidal volumes) can help avoid the high-inspiratory airway pressures associated with decreased cardiac output in tamponade [167].

3.5.4. Where to drain the effusion

The optimal location for a pericardiocentesis is the site at which the visualized fluid pocket is largest and shallowest, with no intervening organs or vital structures. Multiple echocardiographic views should be obtained in order to determine this site. Pushing too hard with the transducer and indenting the skin will provide falsely shorter estimated distances to the effusion. Prior studies have varied in their support for the PLAX, A4C, and SXLA approaches [180-184]. One ED-based retrospective study of 166 pericardial effusions diagnosed by POCUS found that the skin-to-effusion distance the needle must travel was least in the A4C (2.5 cm) and PLAX (2.7 cm) views, as compared to the SXLA view (5.6 cm) [185]. As determined by Clinical Ultrasound Fellowship-trained physicians, they also found a lower predicted complication rate for the PLAX (20.2%) and A4C (31.9%) views, as compared to the SXLA view (79.7%). The most frequently predicted complications for each of the views were poor image quality precluding a safe procedure (30.0%), inability to access the fluid collection (26%), and liver puncture (83.7%), respectively.

Using the PLAX or A4C approaches may raise concern for needle puncture of the lung and an iatrogenic pneumothorax. However, if the lung lies in the proposed needle path, this will be made clear by the sonographic artifacts of lung tissue such as A-lines. Encountering lung tissue will be more likely in patients with chronic obstructive pulmonary disease in whom lung hyperinflation obscures the parasternal views, in which case the SXLA approach would be warranted. Moreover, for the parasternal approach, care must be taken to avoid the internal thoracic artery (also known as the internal mammary artery) that runs approximately 1-3 cm lateral to the left sternal border [154]. The needle should also enter at the superior border of the rib to avoid injuring the neurovascular bundle inferiorly. As an interesting caveat, though the A4C approach risks ventricular puncture due to proximity to the LV, this chamber's thicker wall is more likely to self-seal after inadvertent puncture than will other chambers.

Though thrombocytopenia and coagulopathy are only relative contraindications to pericardiocentesis, the SXLA approach should ideally be avoided in these patients so as to avoid liver injury and associated bleeding. For patients in cardiac arrest, the PLAX approach may be precluded by ongoing chest compressions, defibrillation pads, and other resuscitative activities. The SXLA approach may thus be a safer and more realistic option in cardiac arrest [186].

3.5.5. Pearls and pitfalls for the pericardiocentesis procedure

Pericardiocentesis in the ED has classically been performed with the subxiphoid approach using anatomical landmarks, with a long needle directed towards the left shoulder at a 30° angle to the skin [141]. However, echocardiography can reveal the location and depth of the effusion, intervening structures, and therefore, the ideal entry site. In the echocardiography-assisted method, the operator plots the needle trajectory first and then separately advances the needle along this path. In the echocardiography-guided method, the needle is visualized throughout the entire process of puncturing the skin, advancing towards the effusion, and draining it. The complication rate for pericardiocentesis is much lower when using ultrasound assistance or guidance (0.5-3.7%) as compared to blind or using electrocardiogram assistance (15–20%) [180,187-195].

There are several key considerations when setting up the pericardiocentesis procedure [144,154,196-198]. First, elevating the head of the bed to the semi-reclined position prevents pericardial fluid from gravitating posteriorly, as it would in a supine patient. Secondly, this position may also prevent hypoxia and respiratory distress, which facilitates the safety of the procedure by helping the patient remain still. That will also be supported by injecting liberal amounts of local anesthesia (without epinephrine) along the planned needle tract. Third, intravenous sedation should be avoided in hemodynamically unstable patients, as removing the patient's sympathetic drive can lead to a precipitous drop in SBP.

Fourth, decreasing the depth of the visual field increases the pulse repetition frequency (and thereby the frame rate), which enhances needle visualization. Whereas diagnosis and characterization of a pericardial effusion call for echocardiographic visualization of all cardiac structures, safe needle guidance requires only seeing the desired effusion pocket, which is optimized with less depth in a given view (Fig. 11) (Video 10). If the fluid pocket is superficial enough (within approximately 5 cm depth), the high-frequency linear transducer can be used to provide the optimal resolution. This transducer is already commonly used for other ED procedural skills requiring needle guidance

Downloaded for Anonymous User (n/a) at The University of Arizona from ClinicalKey.com by Elsevier on April 10, 2023. For personal use only. No other uses without permission. Copyright ©2023. Elsevier Inc. All rights reserved.

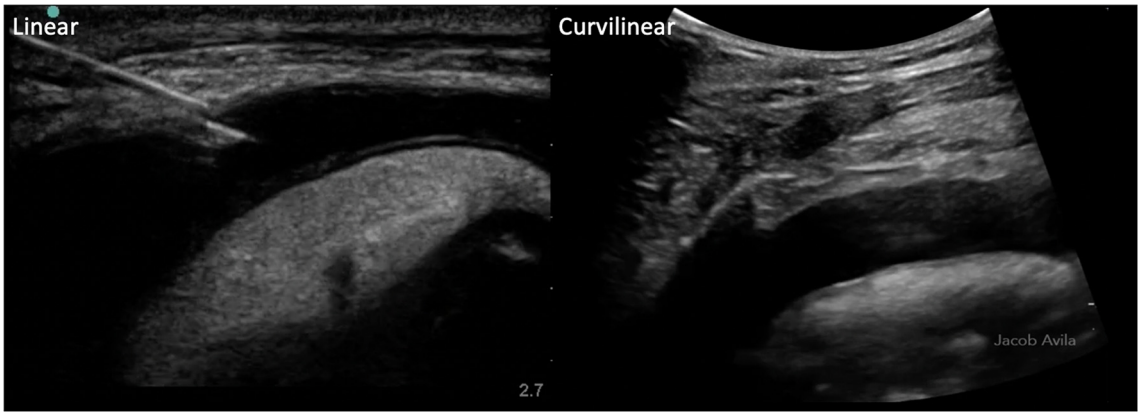

Fig. 11. Pericardiocentesis of an anterior pericardial effusion at low depth (providing optimal needle visualization) using the linear (adapted with permission from Ahad Alhassan MD) and curvilinear transducers.

such as peripheral [199,200] and central line placement [201], arthrocentesis [202], and abscess drainage [203].

Of note, the phased array transducer used for echocardiography is not well-suited for needle guidance. Whereas the piezoelectric crystals of single-element transducers (e.g. linear and curvilinear) are lined up to emit sound waves in a fixed direction (i.e. towards the needle), the scan lines of the phased array transducer emanate in a fan-like formation from the narrow beam point in the center of the transducer face. A differential timed excitation of these piezoelectric crystals causes the beam to be electronically steered and swept through tissue without movement of the transducer itself. Therefore, a smaller proportion of these sound waves encounter the needle directly to be reflected back to the transducer. Instead, the visual "slice" depicted on the screen incorporates all the views insonated from the fan-like emanation of sound waves, and not just those structures to which the transducer is physically pointing.

The next critical safety checkpoint is proper advancement of the pericardiocentesis needle into the pericardial space. First, the plastic cannula tip sits approximately 1 mm proximal to the needle tip visualized under ultrasound guidance. Therefore, the needle should be advanced into the effusion by that amount prior to advancing the cannula. Second, the needle or catheter location should be confirmed prior to attempted aspiration of the effusion. This is best achieved by visualizing the needle or catheter within the effusion using multiple echocardiographic views. A supplementary confirmation technique entails injecting up to 10 mL of agitated saline and visualizing the bubbles within the pericardial space (Fig. 12) (Video 11) [196,204,205]. In the event that a cardiac chamber is inadvertently perforated, the catheter should not be removed until another drainage catheter is properly placed into the pericardial space. If the bleeding persists, surgical repair is needed. Third, if the needle is not long enough or cannot reach the effusion for other reasons, or aspiration through the narrow catheter does not seem feasible (e.g. purulent or clotted material), then surgical drainage is indicated [8].

Once aspiration begins, a hemorrhagic appearance to the fluid warrants that 5-10 mL be expelled onto a gauze pad to examine for small blood clots. If there are no clots, the blood is likely from the pericardial space, as the pericardial mesothelium carries intrinsic fibrinolytic and anti-clotting properties [206]. Conversely, if clots are present, this indicates that either the needle is intracardiac from an inadvertent puncture (blood carries a higher hemoglobin and hematocrit than pericardial fluid), or the clots occurred due to fresh bleeding from an aortic dissection, myocardial rupture, or traumatic hemopericardium (Fig. 13) (Video 12) [207]. In either case, aspiration must be ceased immediately. In the latter scenario, further drainage will allow SBP to rise and promote worsening of the aortic dissection (with potential rupture) or ventricular rupture. As a caveat, aspirated effusion contents can be falsely negative for hemorrhage due to clotted blood products impeding

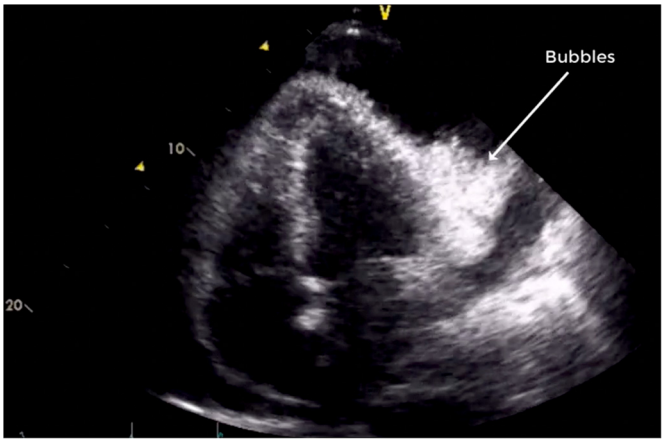

Fig. 12. Administration of agitated saline to confirm pericardiocentesis catheter placement in the pericardial space. In this apical 4-chamber view using the phased array transducer, bubbles produced by the agitated saline appear outside and lateral to the left-sided heart chambers (adapted with permission from Robert Jones DO).

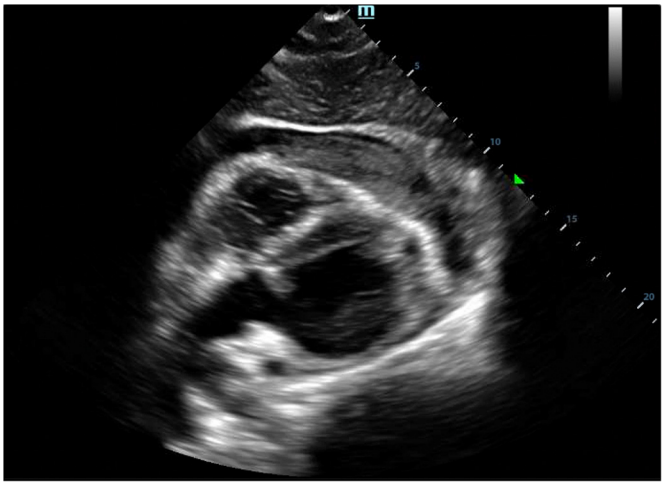

Fig. 13. Traumatic hemopericardium in the subxiphoid long-axis view. Note the hyperechoic clotted blood adjacent to the apex of the heart.

Downloaded for Anonymous User (n/a) at The University of Arizona from ClinicalKey.com by Elsevier on April 10, 2023. For personal use only. No other uses without permission. Copyright ©2023. Elsevier Inc. All rights reserved.

aspiration through the catheter. Additionally, in anticoagulated patients, the aspirated contents may take a longer time to coagulate into clots. Lastly, a myocardial or coronary artery puncture may initially remain clinically silent and later present with delayed hemopericardium.

As aspiration continues, the pericardial fluid should be drained slowly. Though more often associated with surgical drainage, a rapid evacuation of > 1 L of fluid can lead to pericardial decompression syndrome [8,184,208-212]. With a mortality of 29% in 35 cases found between 1983-2013 [208], this condition manifests immediately or up to within 48 hours as cardiogenic pulmonary edema and left-, right-, or biventricular heart failure. It may occur with up to 5% of all pericardiocentesis procedures and is likely underreported [184]. A theorized mechanism is that increased right ventricular preload and chamber enlargement (from removal of the compressive pericardial fluid) distends the muscle fibers and thereby reduces right ventricular systolic function. In conjunction with a persistent catecholaminergic peripheral vasoconstriction, right ventricular compression upon the LV leads to acute left ventricular pressure overload [209]. Patients with chronic PH and right ventricular dysfunction have a particularly high risk for mortality after pericardial drainage [213]. The already pressure-overloaded RV can now enlarge even further, resulting in further septal bowing into the LV and decreased left ventricular preload. Additionally, the reduction in diastolic coronary blood flow associated with right ventricular overdistention leads to chamber ischemia. Treatment for this condition is supportive.

Finally, once initial drainage is completed, the catheter should ideally be left in place (or guided in using Seldinger technique if only a needle was used initially) while it continues to drain > 25 mL per day [8,73,134,196,214]. This will help achieve complete pericardial drainage, as well as facilitate adherence between the visceral and parietal pericardial layers to prevent the effusion from reaccumulating [134]. Intermittent drainage is recommended, with saline left within the catheter to prevent its occlusion [197]. The pericardial effusion recurrence rate for extended drainage is 12-24% compared to 27-55% after simple pericardiocentesis [215,216].

4. Conclusions

Pericardial tamponade is a life-threatening condition requiring timely diagnosis and management. Effusions arise from varying etiologies and can develop into tamponade acutely or sub-acutely. The clinical presentation most often includes dyspnea. Though classically taught, Beck's triad does not actually appear commonly. Echocardiographic findings consist of a pericardial effusion (larger size more often associated with tamponade), diastolic right ventricular collapse (specific), systolic right atrial collapse (sensitive), a plethoric and non-collapsible IVC (sensitive), and respirophasic changes in the mitral and tricuspid inflow velocities that reflect pulsus paradoxus. The decision and timing for performing a pericardiocentesis depend on clinical presentation, patient hemodynamics, effusion etiology, and sonographic findings. Patients with hemodynamic instability, impending deterioration, or cardiac arrest warrant emergent ED pericardiocentesis. Emergent surgical indications include type A aortic dissection causing hemopericardium, ventricular free wall rupture after acute myocardial infarction, severe chest trauma, and iatrogenic hemopericardium when bleeding cannot be controlled percutaneously.

Certain management considerations leading up to the procedure include administration of blood products to patients with traumatic hemopericardium; gentle IVF administration to hypotensive, hypovolemic patients with consideration for vasoactive medications such as epinephrine; and treatment of anticoagulation, coagulopathies, and anemia. Positive-pressure ventilation will decrease cardiac output, and intravenous sedation can remove the patient's sympathetic drive maintaining their blood pressure. Both of those interventions should be avoided if possible. The optimal location for echocardiography-guided pericardiocentesis is the largest and shallowest fluid pocket with as few intervening organs and vital structures as possible. For the procedure itself, elevating the head of the bed to the semi-reclined position to prevent hypoxia, as well as using liberal amounts of local anesthesia, will help the patient remain comfortable and still. Safe needle guidance and confirmation of proper catheter placement should be undertaken using low-depth sonographic views, injection of agitated saline, and evaluation of the initial aspirate for a hemorrhagic appearance. Finally, the pericardial fluid should be drained slowly over time to prevent pericardial decompression syndrome.

Disclosures

JA serves as consultant for Butterfly, Vave, and Echonous. SA, RJA, and BL have no declarations of interest.

Sources of support

N/a

Appendix A. Supplementary data

Supplementary data to this article can be found online at https://doi.org/10.1016/j.ajem.2022.05.001.

References

[1] Klein AL, Abbara S, Agler DA, et al. American Society of Echocardiography clinical recommendations for multimodality cardiovascular imaging of patients with pericardial disease: endorsed by the Society for Cardiovascular Magnetic Resonance and Society of Cardiovascular Computed Tomography. J Am Soc Echocardiogr. 2013;26(9):965–1012 e15.
[2] Spodick DH. Acute cardiac tamponade. N Engl J Med. 2003;349(7):684–90.
[3] Tsang TS, Oh JK, Seward JB. Diagnosis and management of cardiac tamponade in the era of echocardiography. Clin Cardiol. 1999;22(7):446–52.
[4] Saito Y, Donohue A, Attai S, et al. The syndrome of cardiac tamponade with "small" pericardial effusion. Echocardiography. 2008;25(3):321–7.
[5] Kabukcu M, Demircioglu F, Yanik E, et al. Pericardial tamponade and large pericardial effusions: causal factors and efficacy of percutaneous catheter drainage in 50 patients. Tex Heart Inst J. 2004;31(4):398–403.
[6] Reddy PS, Curtiss EI, Uretsky BF. Spectrum of hemodynamic changes in cardiac tamponade. Am J Cardiol. 1990;66(20):1487–91.
[7] Al-Ogaili A, Ayoub A, Fugar S, et al. Cardiac tamponade incidence, demographics and in-hospital outcomes: analysis of the national inpatient sample database. J Am Coll Cardiol. 2018;71(11).
[8] Ristic AD, Imazio M, Adler Y, et al. Triage strategy for urgent management of cardiac tamponade: a position statement of the European Society of Cardiology Working Group on Myocardial and Pericardial Diseases. Eur Heart J. 2014;35(34):2279–84.
[9] Nakai C, Izumi S, Haraguchi T, et al. Acute Type A aortic dissection with cardiopulmonary arrest at presentation. Ann Thorac Surg. 2021;112(4):1210–6.
[10] Kiziltunc E, Unlu S, Yakici IE, et al. Clinical characteristics and prognosis of cardiac tamponade patients: 5year experience at a tertiary center. Herz. 2020;45(7):676–83.
[11] Sagrista-Sauleda J, Merce J, Permanyer-Miralda G, et al. Clinical clues to the causes of large pericardial effusions. Am J Med. 2000;109(2):95–101.
[12] Levy PY, Corey R, Berger P, et al. Etiologic diagnosis of 204 pericardial effusions. Medicine (Baltimore). 2003;82(6):385–91.
[13] Ma W, Liu J, Zeng Y, et al. Causes of moderate to large pericardial effusion requiring pericardiocentesis in 140 Han Chinese patients. Herz. 2012;37(2):183–7.
[14] Sanchez-Enrique C, Nunez-Gil IJ, Viana-Tejedor A, et al. Cause and long-term outcome of cardiac tamponade. Am J Cardiol. 2016;117(4):664–9.
[15] Cornily JC, Pennec PY, Castellant P, et al. Cardiac tamponade in medical patients: a 10-year follow-up survey. Cardiology. 2008;111(3):197–201.
[16] Levy PY, Fournier PE, Charrel R, et al. Molecular analysis of pericardial fluid: a 7-year experience. Eur Heart J. 2006;27(16):1942–6.
[17] Orbach A, Schliamser JE, Flugelman MY, et al. Contemporary evaluation of the causes of cardiac tamponade: acute and long-term outcomes. Cardiol J. 2016;23(1):57–63.
[18] Pennacchioni A, Nanni G, Sgura FA, et al. Percutaneous pericardiocentesis for pericardial effusion: predictors of mortality and outcomes. Intern Emerg Med. 2021;16(7):1771–7.
[19] Guberman BA, Fowler NO, Engel PJ, et al. Cardiac tamponade in medical patients. Circulation. 1981;64(3):633–40.
[20] Colombo A, Olson HG, Egan J, et al. Etiology and prognostic implications of a large pericardial effusion in men. Clin Cardiol. 1988;11(6):389–94.
[21] Eke OF, Selame L, Gullikson J, et al. Timing of pericardiocentesis and clinical outcomes: Is earlier pericardiocentesis better? Am J Emerg Med. 2022;54:202–7.

Downloaded for Anonymous User (n/a) at The University of Arizona from ClinicalKey.com by Elsevier on April 10, 2023. For personal use only. No other uses without permission. Copyright ©2023. Elsevier Inc. All rights reserved.

[22] De Filippo O, Gatti P, Rettegno S, et al. Is pericardial effusion a negative prognostic marker? Meta-analysis of outcomes of pericardial effusion. J Cardiovasc Med (Hagerstown). 2019;20(1):39–45.
[23] Stolz L, Valenzuela J, Situ-LaCasse E, et al. Clinical and historical features of emergency department patients with pericardial effusions. World J Emerg Med. 2017;8(1):29–33.
[24] Eisenberg MJ, Oken K, Guerrero S, et al. Prognostic value of echocardiography in hospitalized patients with pericardial effusion. Am J Cardiol. 1992;70(9):934–9.
[25] Leehey DJ, Daugirdas JT, Popli S, et al. Predicting need for surgical drainage of pericardial effusion in patients with end-stage renal disease. Int J Artif Organs. 1989;12(10):618–25.
[26] Luft FC, Gilman JK, Weyman AE. Pericarditis in the patient with uremia: clinical and echocardiographic evaluation. Nephron. 1980;25(4):160–6.
[27] Peraino RA. Pericardial effusion in patients treated with maintenance dialysis. Am J Nephrol. 1983;3(6):319–22.
[28] Ribot S, Frankel HJ, Gielchinsky I, et al. Treatment of uremic pericarditis. Clin Nephrol. 1974;2(4):127–30.
[29] Kramer P, Wigger W, Scheler F. Management of uraemic pericarditis. Br Med J. 1975;4(5996):564–6.
[30] De Pace NL, Nestico PF, Schwartz AB, et al. Predicting success of intensive dialysis in the treatment of uremic pericarditis. Am J Med. 1984;76(1):38–46.
[31] Renfrew R, Buselmeier TJ, Kjellstrand CM. Pericarditis and renal failure. Annu Rev Med. 1980;31:345–60.
[32] Imazio M, Lazaros G, Valenti A, et al. Outcomes of idiopathic chronic large pericardial effusion. Heart. 2019;105(6):477–81.
[33] Merce J, Sagrista-Sauleda J, Permanyer-Miralda G, et al. Should pericardial drainage be performed routinely in patients who have a large pericardial effusion without tamponade? Am J Med. 1998;105(2):106–9.
[34] Sagrista-Sauleda J, Angel J, Permanyer-Miralda G, et al. Long-term follow-up of idiopathic chronic pericardial effusion. N Engl J Med. 1999;341(27):2054–9.
[35] Lazaros G, Antonopoulos AS, Lazarou E, et al. Long-term outcome of pericardial drainage in cases of chronic, large, hemodynamically insignificant, C-reactive protein negative, *idiopathic pericardial effusions*. Am J Cardiol. 2020;126:89–93.
[36] Markiewicz W, Borovik R, Ecker S. Cardiac tamponade in medical patients: treatment and prognosis in the echocardiographic era. Am Heart J. 1986;111(6):1138–42.
[37] Gong W, Nie S. New clinical classification for ventricular free wall rupture following acute myocardial infarction. Cardiovasc Ther. 2021;2021:1716546.
[38] Sanmartin-Fernandez M, Raposeiras-Roubin S, Anguita-Sanchez M, et al. In-hospital outcomes of mechanical complications in acute myocardial infarction: analysis from a nationwide Spanish database. Cardiol J. 2021;28(4):589–97.
[39] Lopez-Sendon J, Gurfinkel EP, Lopez de Sa E, et al. Factors related to heart rupture in acute coronary syndromes in the Global Registry of Acute Coronary Events. Eur Heart J. 2010;31(12):1449–56.
[40] Roy CL, Minor MA, Brookhart MA, et al. Does this patient with a pericardial effusion have cardiac tamponade? JAMA. 2007;297(16):1810–8.
[41] Kapoor T, Locurto M, Farina GA, et al. Hypotension is uncommon in patients presenting to the emergency department with non-traumatic cardiac tamponade. J Emerg Med. 2012;42(2):220–6.
[42] Gibbs CR, Watson RD, Singh SP, et al. Management of pericardial effusion by drainage: a survey of 10 years' experience in a city centre general hospital serving a multiracial population. Postgrad Med J. 2000;76(902):809–13.
[43] Levine MJ, Lorell BH, Diver DJ, et al. Implications of echocardiographically assisted diagnosis of pericardial tamponade in contemporary medical patients: detection before hemodynamic embarrassment. J Am Coll Cardiol. 1991;17(1):59–65.
[44] Cooper JP, Oliver RM, Currie P, et al. How do the clinical findings in patients with pericardial effusions influence the success of aspiration? Br Heart J. 1995;73(4):351–4.
[45] Hanson MG, Chan B. The role of point-of-care ultrasound in the diagnosis of pericardial effusion: a single academic center retrospective study. Ultrasound J. 2021;13(1):2.
[46] Duanmu Y, Choi DS, Tracy S, et al. Development and validation of a novel prediction score for cardiac tamponade in emergency department patients with pericardial effusion. Eur Heart J Acute Cardiovasc Care. 2021;10(5):542–9.
[47] Sagrista-Sauleda J, Angel J, Sambola A, et al. Low-pressure cardiac tamponade: clinical and hemodynamic profile. Circulation. 2006;114(9):945–52.
[48] Beck C. Two cardiac compression triads. JAMA. 1935;104(9):714–6.
[49] Gandhi S, Schneider A, Mohiuddin S, et al. Has the clinical presentation and clinician's index of suspicion of cardiac tamponade changed over the past decade? Echocardiography. 2008;25(3):237–41.
[50] Larose E, Ducharme A, Mercier LA, et al. Prolonged distress and clinical deterioration before pericardial drainage in patients with cardiac tamponade. Can J Cardiol. 2000;16(3):331–6.
[51] Argulian E, Herzog E, Halpern DG, et al. Paradoxical hypertension with cardiac tamponade. Am J Cardiol. 2012;110(7):1066–9.
[52] Brown J, MacKinnon D, King A, et al. Elevated arterial blood pressure in cardiac tamponade. N Engl J Med. 1992;327(7):463–6.
[53] Cogswell TL, Bernath GA, Raff H, et al. Total peripheral resistance during cardiac tamponade: adrenergic and angiotensin roles. Am J Phys. 1986;251(5 Pt 2):R916–22.
[54] Kaszaki J, Nagy S, Tarnoky K, et al. Humoral changes in shock induced by cardiac tamponade. Circ Shock. 1989;29(2):143–53.
[55] Cook DJ. Clinical assessment of central venous pressure in the critically ill. Am J Med Sci. 1990;299(3):175–8.
[56] Davison R, Cannon R. Estimation of central venous pressure by examination of jugular veins. Am Heart J. 1974;87(3):279–82.
[57] Singh S, Wann LS, Schuchard GH, et al. Right ventricular and right atrial collapse in patients with cardiac tamponade–a combined echocardiographic and hemodynamic study. Circulation. 1984;70(6):966–71.
[58] Reddy PS, Curtiss EI, O'Toole JD, et al. Cardiac tamponade: hemodynamic observations in man. Circulation. 1978;58(2):265–72.
[59] Alerhand S, Carter JM. What echocardiographic findings suggest a pericardial effusion is causing tamponade? Am J Emerg Med. 2019;37(2):321–6.
[60] Cheitlin MD, Armstrong WF, Aurigemma GP, et al. ACC/AHA/ASE 2003 guideline update for the clinical application of echocardiography: summary article: a report of the American College of Cardiology/American Heart Association Task Force on Practice Guidelines (ACC/AHA/ASE Committee to Update the 1997 Guidelines for the Clinical Application of Echocardiography). Circulation. 2003;108(9):1146–62.
[61] Adler Y, Charron P, Imazio M, et al. 2015 ESC Guidelines for the diagnosis and management of pericardial diseases: The Task Force for the Diagnosis and Management of Pericardial Diseases of the European Society of Cardiology (ESC)Endorsed by: The European Association for Cardio-Thoracic Surgery (EACTS). Eur Heart J. 2015;36(42):2921–64.
[62] Eisenberg MJ, Schiller NB. Bayes' theorem and the echocardiographic diagnosis of cardiac tamponade. Am J Cardiol. 1991;68(11):1242–4.
[63] Alpert EA, Amit U, Guranda L, et al. Emergency department point-of-care ultrasonography improves time to pericardiocentesis for clinically significant effusions. Clin Exp Emerg Med. 2017;4(3):128–32.
[64] Plummer D, Brunette D, Asinger R, et al. Emergency department echocardiography improves outcome in penetrating cardiac injury. Ann Emerg Med. 1992;21(6):709–12.
[65] Nagy KK, Lohmann C, Kim DO, et al. Role of echocardiography in the diagnosis of occult penetrating cardiac injury. J Trauma. 1995;38(6):859–62.
[66] Aaland MO, Bryan 3rd FC, Sherman R. Two-dimensional echocardiogram in hemodynamically stable victims of penetrating precordial trauma. Am Surg. 1994;60(6):412–5.
[67] Freshman SP, Wisner DH, Weber CJ. 2-D echocardiography: emergent use in the evaluation of penetrating precordial trauma. J Trauma. 1991;31(7):902–5. discussion 905-6.
[68] Jimenez E, Martin M, Krukenkamp I, et al. Subxiphoid pericardiotomy versus echocardiography: a prospective evaluation of the diagnosis of occult penetrating cardiac injury. Surgery. 1990;108(4):676–9. discussion 679-80.
[69] Labovitz AJ, Noble VE, Bierig M, et al. Focused cardiac ultrasound in the emergent setting: a consensus statement of the American Society of Echocardiography and American College of Emergency Physicians. J Am Soc Echocardiogr. 2010;23(12):1225–30.
[70] Mandavia DP, Hoffner RJ, Mahaney K, et al. Bedside echocardiography by emergency physicians. Ann Emerg Med. 2001;38(4):377–82.
[71] Lanoix R, Leak LV, Gaeta T, et al. A preliminary evaluation of emergency ultrasound in the setting of an emergency medicine training program. Am J Emerg Med. 2000;18(1):41–5.
[72] Cosyns B, Plein S, Nihoyanopoulos P, et al. European Association of Cardiovascular Imaging (EACVI) position paper: Multimodality imaging in pericardial disease. Eur Heart J Cardiovasc Imaging. 2015;16(1):12–31.
[73] Adler Y, Charron P. The 2015 ESC Guidelines on the diagnosis and management of pericardial diseases. Eur Heart J. 2015;36(42):2873–4.
[74] Imazio M, Brucato A, Trinchero R, et al. Diagnosis and management of pericardial diseases. Nat Rev Cardiol. 2009;6(12):743–51.
[75] Hoit BD. Pericardial disease and pericardial tamponade. Crit Care Med. 2007;35(8 Suppl):S355–64.
[76] Wann S, Passen E. Echocardiography in pericardial disease. J Am Soc Echocardiogr. 2008;21(1):7–13.
[77] Ginghina C, Beladan CC, Iancu M, et al. Respiratory maneuvers in echocardiography: a review of clinical applications. Cardiovasc Ultrasound. 2009;7:42.
[78] Fenichel NM, Arora J, Khan R, et al. The effect of respiratory motion on the echocardiogram. Chest. 1976;65(5):655.
[79] Rifkin RD, Isner JM, Carter BL, et al. Combined posteroanterior subepicardial fat simulating the echocardiographic diagnosis of pericardial effusion. J Am Coll Cardiol. 1984;3(5):1333–9.
[80] Haaz WS, Mintz GS, Kotler MN, et al. Two dimensional echocardiographic recognition of the descending thoracic aorta: value in differentiating pericardial from pleural effusions. Am J Cardiol. 1980;46(5):739–43.
[81] Come PC, Riley MF, Fortuin NJ, et al. Echocardiographic mimicry of pericardial effusion. Am J Cardiol. 1981;47(2):365–70.
[82] Leimgruber PP, Klopfenstein HS, Wann LS, et al. The hemodynamic derangement associated with right ventricular diastolic collapse in cardiac tamponade: an experimental echocardiographic study. Circulation. 1983;68(3):612–20.
[83] Gaffney FA, Keller AM, Peshock RM, et al. Pathophysiologic mechanisms of cardiac tamponade and pulsus alternans shown by echocardiography. Am J Cardiol. 1984;53(11):1662–6.
[84] Guntheroth WG. Sensitivity and specificity of echocardiographic evidence of tamponade: implications for ventricular interdependence and pulsus paradoxus. Pediatr Cardiol. 2007;28(5):358–62.
[85] Merce J, Sagrista-Sauleda J, Permanyer-Miralda G, et al. Correlation between clinical and Doppler echocardiographic findings in patients with moderate and large pericardial effusion: implications for the diagnosis of cardiac tamponade. Am Heart J. 1999;138(4 Pt 1):759–64.
[86] Armstrong WF, Schilt BF, Helper DJ, et al. Diastolic collapse of the right ventricle with cardiac tamponade: an echocardiographic study. Circulation. 1982;65(7):1491–6.
[87] Engel PJ, Hon H, Fowler NO, et al. Echocardiographic study of right ventricular wall motion in cardiac tamponade. Am J Cardiol. 1982;50(5):1018–21.

Downloaded for Anonymous User (n/a) at The University of Arizona from ClinicalKey.com by Elsevier on April 10, 2023. For personal use only. No other uses without permission. Copyright ©2023. Elsevier Inc. All rights reserved.

[88] Singh S, Wann LS, Klopfenstein HS, et al. Usefulness of right ventricular diastolic collapse in diagnosing cardiac tamponade and comparison to pulsus paradoxus. Am J Cardiol. 1986;57(8):652–6.
[89] Shimony A, Fox BD, Langleben D, et al. Incidence and significance of pericardial effusion in patients with pulmonary arterial hypertension. Can J Cardiol. 2013;29(6):678–82.
[90] Natanzon A, Kronzon I. Pericardial and pleural effusions in congestive heart failure-anatomical, pathophysiologic, and clinical considerations. Am J Med Sci. 2009;338(3):211–6.
[91] Hoit BD, Fowler NO. Influence of acute right ventricular dysfunction on cardiac tamponade. J Am Coll Cardiol. 1991;18(7):1787–93.
[92] Santamore WP, Heckman JL, Bove AA. Right and left ventricular pressure-volume response to elevated pericardial pressure. Am Rev Respir Dis. 1986;134(1):101–7.
[93] Ceriani E, Cogliati C. Update on bedside ultrasound diagnosis of pericardial effusion. Intern Emerg Med. 2016;11(3):477–80.
[94] Mahmud E, Raisinghani A, Hassankhani A, et al. Correlation of left ventricular diastolic filling characteristics with right ventricular overload and pulmonary artery pressure in chronic thromboembolic pulmonary hypertension. J Am Coll Cardiol. 2002;40(2):318–24.
[95] Plotnick GD, Rubin DC, Feliciano Z, et al. Pulmonary hypertension decreases the predictive accuracy of echocardiographic clues for cardiac tamponade. Chest. 1995;107(4):919–24.
[96] Sahay S, Tonelli AR. Pericardial effusion in pulmonary arterial hypertension. Pulm Circ. 2013;3(3):467–77.
[97] Klopfenstein HS, Cogswell TL, Bernath GA, et al. Alterations in intravascular volume affect the relation between right ventricular diastolic collapse and the hemodynamic severity of cardiac tamponade. J Am Coll Cardiol. 1985;6(5):1057–63.
[98] Antman EM, Cargill V, Grossman W. Low-pressure cardiac tamponade. Ann Intern Med. 1979;91(3):403–6.
[99] Perez-Casares A, Cesar S, Brunet-Garcia L, et al. Echocardiographic evaluation of pericardial effusion and cardiac tamponade. Front Pediatr. 2017;5:79.
[100] Kronzon I, Cohen ML, Winer HE. Diastolic atrial compression: a sensitive echocardiographic sign of cardiac tamponade. J Am Coll Cardiol. 1983;2(4):770–5.
[101] Gillam LD, Guyer DE, Gibson TC, et al. Hydrodynamic compression of the right atrium: a new echocardiographic sign of cardiac tamponade. Circulation. 1983;68(2):294–301.
[102] Materazzo C, Piotti P, Meazza R, et al. Respiratory changes in transvalvular flow velocities versus two-dimensional echocardiographic findings in the diagnosis of cardiac tamponade. Ital Heart J. 2003;4(3):186–92.
[103] Fast J, Wielenga RP, Jansen E, et al. Abnormal wall movements of the right ventricle and both atria in patients with pericardial effusion as indicators of cardiac tamponade. Eur Heart J. 1986;7(5):431–6.
[104] Field LC, Guldan 3rd GJ, Finley AC. Echocardiography in the intensive care unit. Semin Cardiothorac Vasc Anesth. 2011;15(1-2):25–39.
[105] Elavunkal J, Bright L, Stone MB. Emergency ultrasound identification of loculated pericardial effusion: the importance of multiple cardiac views. Acad Emerg Med. 2011;18(3):e29.
[106] Kronzon I, Cohen ML, Winer HE. Cardiac tamponade by loculated pericardial hematoma: limitations of M-mode echocardiography. J Am Coll Cardiol. 1983;1(3):913–5.
[107] Berge KH, Lanier WL, Reeder GS. Occult cardiac tamponade detected by transesophageal echocardiography. Mayo Clin Proc. 1992;67(7):667–70.
[108] Fusman B, Schwinger ME, Charney R, et al. Isolated collapse of left-sided heart chambers in cardiac tamponade: demonstration by two-dimensional echocardiography. Am Heart J. 1991;121(2 Pt 1):613–6.
[109] Bommer WJ, Follette D, Pollock M, et al. Tamponade in patients undergoing cardiac surgery: a clinical-echocardiographic diagnosis. Am Heart J. 1995;130(6):1216–23.
[110] Chuttani K, Tischler MD, Pandian NG, et al. Diagnosis of cardiac tamponade after cardiac surgery: relative value of clinical, echocardiographic, and hemodynamic signs. Am Heart J. 1994;127(4 Pt 1):913–8.
[111] Chuttani K, Pandian NG, Mohanty PK, et al. Left ventricular diastolic collapse. An echocardiographic sign of regional cardiac tamponade. Circulation. 1991;83(6):1999–2006.
[112] Aqel RA, Aljaroudi W, Hage FG, et al. Left ventricular collapse secondary to pericardial effusion treated with pericardicentesis and percutaneous pericardiotomy in severe pulmonary hypertension. Echocardiography. 2008;25(6):658–61.
[113] D'Cruz IA, Kensey K, Campbell C, et al. Two-dimensional echocardiography in cardiac tamponade occurring after cardiac surgery. J Am Coll Cardiol. 1985;5(5):1250–2.
[114] Gowani SA, Danielian A, Villaneuva J, et al. Large pleural effusions causing cardiac tamponade: a case report and review of the literature. Conn Med. 2014;78(3):149–52.
[115] Bilku RS, Bilku DK, Rosin MD, et al. Left ventricular diastolic collapse and late regional cardiac tamponade postcardiac surgery caused by large left pleural effusion. J Am Soc Echocardiogr. 2008.;21(8) p. 978 e9-11.
[116] Kopterides P, Lignos M, Papanikolaou S, et al. Pleural effusion causing cardiac tamponade: report of two cases and review of the literature. Heart Lung. 2006;35(1):66–7.
[117] Kaplan LM, Epstein SK, Schwartz SL, et al. Clinical, echocardiographic, and hemodynamic evidence of cardiac tamponade caused by large pleural effusions. Am J Respir Crit Care Med. 1995;151(3 Pt 1):904–8.
[118] Kisanuki A, Shono H, Kiyonaga K, et al. Two-dimensional echocardiographic demonstration of left ventricular diastolic collapse due to compression by pleural effusion. Am Heart J. 1991;122(4 Pt 1):1173–5.
[119] Kuvin JT, Harati NA, Pandian NG, et al. Postoperative cardiac tamponade in the modern surgical era. Ann Thorac Surg. 2002;74(4):1148–53.
[120] Himelman RB, Kircher B, Rockey DC, et al. Inferior vena cava plethora with blunted respiratory response: a sensitive echocardiographic sign of cardiac tamponade. J Am Coll Cardiol. 1988;12(6):1470–7.
[121] Settle HP, Adolph RJ, Fowler NO, et al. Echocardiographic study of cardiac tamponade. Circulation. 1977;56(6):951–9.
[122] Walsh BM, Tobias LA. Low-pressure pericardial tamponade: case report and review of the literature. J Emerg Med. 2017;52(4):516–22.
[123] Rudski LG, Lai WW, Afilalo J, et al. Guidelines for the echocardiographic assessment of the right heart in adults: a report from the American Society of Echocardiography endorsed by the European Association of Echocardiography, a registered branch of the European Society of Cardiology, and the Canadian Society of Echocardiography. J Am Soc Echocardiogr. 2010;23(7):685–713. quiz 786-8.
[124] Leeman DE, Levine MJ, Come PC. Doppler echocardiography in cardiac tamponade: exaggerated respiratory variation in transvalvular blood flow velocity integrals. J Am Coll Cardiol. 1988;11(3):572–8.
[125] Appleton CP, Hatle LK, Popp RL. Cardiac tamponade and pericardial effusion: respiratory variation in transvalvular flow velocities studied by Doppler echocardiography. J Am Coll Cardiol. 1988;11(5):1020–30.
[126] Hoit BD, Gabel M, Fowler NO. Cardiac tamponade in left ventricular dysfunction. Circulation. 1990;82(4):1370–6.
[127] Imazio M, De Ferrari GM. Cardiac tamponade: an educational review. Eur Heart J Acute Cardiovasc Care. 2020..
[128] Gonzalez MS, Basnight MA, Appleton CP. Experimental pericardial effusion: relation of abnormal respiratory variation in mitral flow velocity to hemodynamics and diastolic right heart collapse. J Am Coll Cardiol. 1991;17(1):239–48.
[129] Hoit BD, Shaw D. The paradoxical pulse in tamponade: mechanisms and echocardiographic correlates. Echocardiography. 1994;11(5):477–87.
[130] Faehnrich JA, Noone Jr RB, White WD, et al. Effects of positive-pressure ventilation, pericardial effusion, and cardiac tamponade on respiratory variation in transmitral flow velocities. J Cardiothorac Vasc Anesth. 2003;17(1):45–50.
[131] Goldstein JA. Cardiac tamponade in the interventional era: a paradigm shift in etiology and outcomes. Catheter Cardiovasc Interv. 2020;95(3):387–8.
[132] Soler-Soler J, Sagrista-Sauleda J, Permanyer-Miralda G. Management of pericardial effusion. Heart. 2001;86(2):235–40.
[133] Imazio M, Adler Y. Management of pericardial effusion. Eur Heart J. 2013;34(16):1186–97.
[134] Sagrista-Sauleda J, Merce AS, Soler-Soler J. Diagnosis and management of pericardial effusion. World J Cardiol. 2011;3(5):135–43.
[135] Imazio M, Spodick DH, Brucato A, et al. Controversial issues in the management of pericardial diseases. Circulation. 2010;121(7):916–28.
[136] Imazio M, Mayosi BM, Brucato A, et al. Triage and management of pericardial effusion. J Cardiovasc Med (Hagerstown). 2010;11(12):928–35.
[137] Maisch B, Ristic A, Pankuweit S. Evaluation and management of pericardial effusion in patients with neoplastic disease. Prog Cardiovasc Dis. 2010;53(2):157–63.
[138] Imazio M, Cecchi E, Demichelis B, et al. Indicators of poor prognosis of acute pericarditis. Circulation. 2007;115(21):2739–44.
[139] Gowda RM, Khan IA, Mehta NJ, et al. Cardiac tamponade in patients with human immunodeficiency virus disease. Angiology. 2003;54(4):469–74.
[140] Chen Y, Brennessel D, Walters J, et al. Human immunodeficiency virus-associated pericardial effusion: report of 40 cases and review of the literature. Am Heart J. 1999;137(3):516–21.
[141] Maisch B, Seferovic PM, Ristic AD, et al. Guidelines on the diagnosis and management of pericardial diseases executive summary; The Task force on the diagnosis and management of pericardial diseases of the European society of cardiology. Eur Heart J. 2004;25(7):587–610.
[142] Isselbacher EM, Cigarroa JE, Eagle KA. Cardiac tamponade complicating proximal aortic dissection. Is pericardiocentesis harmful? Circulation. 1994;90(5):2375–8.
[143] Coplan NL, Goldman B, Mechanic G, et al. Sudden hemodynamic collapse following relief of cardiac tamponade in aortic dissection. Am Heart J. 1986;111(2):405–6.
[144] Flint N, Siegel RJ. Echo-guided pericardiocentesis: when and how should it be performed? Curr Cardiol Rep. 2020;22(8):71.
[145] Silvestry FE, Kerber RE, Brook MM, et al. Echocardiography-guided interventions. J Am Soc Echocardiogr. 2009;22(3):213–31. quiz 316-7.
[146] Kitamura T, Miyaji K. Emergency pericardial drainage without aortic repair for type A intramural haematoma complicated by cardiac tamponade. Interact Cardiovasc Thorac Surg. 2021;32(6):953–5.
[147] Cruz I, Stuart B, Caldeira D, et al. Controlled pericardiocentesis in patients with cardiac tamponade complicating aortic dissection: experience of a centre without cardiothoracic surgery. Eur Heart J Acute Cardiovasc Care. 2015;4(2):124–8.
[148] Hayashi T, Tsukube T, Yamashita T, et al. Impact of controlled pericardial drainage on critical cardiac tamponade with acute type A aortic dissection. Circulation. 2012;126(11 Suppl 1):S97–S101.
[149] Garcia-Jimenez A, Peraza Torres A, Martinez Lopez G, et al. Cardiac tamponade by aortic dissection in a hospital without cardiothoracic surgery. Chest. 1993;104(1):290–1.
[150] Aravot DJ, Vidne BA. Prevention of hemodynamic collapse after relief of cardiac tamponade in aortic dissection. Am Heart J. 1987;113(6):1537–8.
[151] Argulian E, Halpern DG, Aziz EF, et al. Novel "CHASER" pathway for the management of pericardial disease. Crit Pathw Cardiol. 2011;10(2):57–63.
[152] Halpern DG, Argulian E, Briasoulis A, et al. A novel pericardial effusion scoring index to guide decision for drainage. Crit Pathw Cardiol. 2012;11(2):85–8.
[153] Little WC, Freeman GL. Pericardial disease. Circulation. 2006;113(12):1622–32.
[154] Luis SA, Kane GC, Luis CR, et al. Overview of optimal techniques for pericardiocentesis in contemporary practice. Curr Cardiol Rep. 2020;22(8):60.

Downloaded for Anonymous User (n/a) at The University of Arizona from ClinicalKey.com by Elsevier on April 10, 2023. For personal use only. No other uses without permission. Copyright ©2023. Elsevier Inc. All rights reserved.

[155] Ryu AJ, Kane GC, Pislaru SV, et al. Bleeding complications of ultrasound-guided pericardiocentesis in the presence of coagulopathy or thrombocytopenia. J Am Soc Echocardiogr. 2020;33(3):399–401.
[156] Iliescu C, Khair T, Marmagkiolis K, et al. Echocardiography and fluoroscopy-guided pericardiocentesis for cancer patients with cardiac tamponade and thrombocytopenia. J Am Coll Cardiol. 2016;68(7):771–3.
[157] Warner MA, Woodrum D, Hanson A, et al. Preprocedural platelet transfusion for patients with thrombocytopenia undergoing interventional radiology procedures is not associated with reduced bleeding complications. Transfusion. 2017;57(4):890–8.
[158] Cooper FW, Stead EA, Warren JV. The beneficial effect of intravenous infusions in acute pericardial temponade. Ann Surg. 1944;120(6):822–5.
[159] Singh V, Dwivedi SK, Chandra S, et al. Optimal fluid amount for haemodynamic benefit in cardiac tamponade. Eur Heart J Acute Cardiovasc Care. 2014;3(2):158–64.
[160] Sagrista-Sauleda J, Angel J, Sambola A, et al. Hemodynamic effects of volume expansion in patients with cardiac tamponade. Circulation. 2008;117(12):1545–9.
[161] Imazio M. Volume expansion as temporizing measure for cardiac tamponade: when and how? Eur Heart J Acute Cardiovasc Care. 2014;3(2):165–6.
[162] Kerber RE, Gascho JA, Litchfield R, et al. Hemodynamic effects of volume expansion and nitroprusside compared with pericardiocentesis in patients with acute cardiac tamponade. N Engl J Med. 1982;307(15):929–31.
[163] Gascho JA, Martins JB, Marcus ML, et al. Effects of volume expansion and vasodilators in acute pericardial tamponade. Am J Phys. 1981;240(1):H49–53.
[164] Isaacs JP, Berglund E, Sarnoff SJ. Ventricular function. III. The pathologic physiology of acute cardiac tamponade studied by means of ventricular function curves. Am Heart J. 1954;48(1):66–76.
[165] Kearns MJ, Walley KR. Tamponade: hemodynamic and echocardiographic diagnosis. Chest. 2018;153(5):1266–75.
[166] Martins JB, Manuel WJ, Marcus ML, et al. Comparative effects of catecholamines in cardiac tamponade: experimental and clinical studies. Am J Cardiol. 1980;46(1):59–66.
[167] Mattila I, Takkunen O, Mattila P, et al. Cardiac tamponade and different modes of artificial ventilation. Acta Anaesthesiol Scand. 1984;28(2):236–40.
[168] Finegan RE, Schroll M, Robison S, et al. Action of pharmacologic agents in experimental cardiac tamponade. Am Heart J. 1971;81(2):220–6.
[169] Fowler NO, Holmes JC. Hemodynamic effects of isoproterenol and norepinephrine in acute cardiac tamponade. J Clin Invest. 1969;48(3):502–7.
[170] Treister B, Gianelly RE, Cohn KE, et al. The circulatory effects of isoproterenol, acetylstrophanthidin, and volume loading in acute pericardial tamponade. Cardiovasc Res. 1969;3(3):299–305.
[171] Millard RW, Fowler NO, Gabel M. Hemodynamic and regional blood flow distribution responses to dextran, hydralazine, isoproterenol and amrinone during experimental cardiac tamponade. J Am Coll Cardiol. 1983;1(6):1461–70.
[172] Rowan SB, Krantz MJ. Paradoxical decrease in blood pressure after relief of cardiac tamponade: the role of sympathetic activity. Med Sci Monit. 2006.;12(2) p. CS16-9.
[173] Moller CT, Schoonbee CG, Rosendorff C. Haemodynamics of cardiac tamponade during various modes of ventilation. Br J Anaesth. 1979;51(5):409–15.
[174] Stanley TH, Weidauer HE. Anesthesia for the patient with cardiac tamponade. Anesth Analg. 1973;52(1):110–4.
[175] Lake CL. Anesthesia and pericardial disease. Anesth Analg. 1983;62(4):431–43.
[176] Webster JA, Self DD. Anesthesia for pericardial window in a pregnant patient with cardiac tamponade and mediastinal mass. Can J Anaesth. 2003;50(8):815–8.
[177] Aye T, Milne B. Ketamine anesthesia for pericardial window in a patient with pericardial tamponade and severe COPD. Can J Anaesth. 2002;49(3):283–6.
[178] Koller ME, Smith RB, Sjostrand U, et al. Effects of hypo-, normo-, and hypercarbia in dogs with acute cardiac tamponade. Anesth Analg. 1983;62(2):181–5.
[179] Breen PH, MacVay MA. Pericardial tamponade: a case for awake endotracheal intubation. Anesth Analg. 1996;83(3):658.
[180] Tsang TS, Enriquez-Sarano M, Freeman WK, et al. Consecutive 1127 therapeutic echocardiographically guided pericardiocenteses: clinical profile, practice patterns, and outcomes spanning 21 years. Mayo Clin Proc. 2002;77(5):429–36.
[181] Law MA, Borasino S, Kalra Y, et al. Novel, long-axis in-plane ultrasound-guided pericardiocentesis for postoperative pericardial effusion drainage. Pediatr Cardiol. 2016;37(7):1328–33.
[182] Cho BC, Kang SM, Kim DH, et al. Clinical and echocardiographic characteristics of pericardial effusion in patients who underwent echocardiographically guided pericardiocentesis: Yonsei Cardiovascular Center experience, 1993-2003. Yonsei Med J. 2004;45(3):462–8.
[183] Hanaki Y, Kamiya H, Todoroki H, et al. New two-dimensional, echocardiographically directed pericardiocentesis in cardiac tamponade. Crit Care Med. 1990;18(7):750–3.
[184] Sinnaeve PR, Adriaenssens T. A contemporary look at pericardiocentesis. Trends Cardiovasc Med. 2019;29(7):375–83.
[185] Stolz L, Situ-LaCasse E, Acuna J, et al. What is the ideal approach for emergent pericardiocentesis using point-of-care ultrasound guidance? World J Emerg Med. 2021;12(3):169–73.
[186] Flower L, Olusanya O, Madhivathanan PR. The use of critical care echocardiography in peri-arrest and cardiac arrest scenarios: Pros, cons and what the future holds. J Intensive Care Soc. 2021;22(3):230–40.
[187] Akyuz S, Zengin A, Arugaslan E, et al. Echo-guided pericardiocentesis in patients with clinically significant pericardial effusion. Outcomes over a 10-year period. Herz. 2015;40(Suppl. 2):153–9.
[188] Callahan JA, Seward JB, Nishimura RA, et al. Two-dimensional echocardiographically guided pericardiocentesis: experience in 117 consecutive patients. Am J Cardiol. 1985;55(4):476–9.
[189] Maggiolini S, Gentile G, Farina A, et al. Safety, efficacy, and complications of pericardiocentesis by real-time echo-monitored procedure. Am J Cardiol. 2016;117(8):1369–74.
[190] Duvernoy O, Borowiec J, Helmius G, et al. Complications of percutaneous pericardiocentesis under fluoroscopic guidance. Acta Radiol. 1992;33(4):309–13.
[191] Tsang TS, Barnes ME, Hayes SN, et al. Clinical and echocardiographic characteristics of significant pericardial effusions following cardiothoracic surgery and outcomes of echo-guided pericardiocentesis for management: Mayo Clinic experience, 1979-1998. Chest. 1999;116(2):322–31.
[192] Bastian A, Meissner A, Lins M, et al. Pericardiocentesis: differential aspects of a common procedure. Intensive Care Med. 2000;26(5):572–6.
[193] Ho MY, Wang JL, Lin YS, et al. Pericardiocentesis adverse event risk factors: a nationwide population-based cohort study. Cardiology. 2015;130(1):37–45.
[194] Wong B, Murphy J, Chang CJ, et al. The risk of pericardiocentesis. Am J Cardiol. 1979;44(6):1110–4.
[195] Bishop Jr LH, Estes Jr EH, McIntosh HD. The electrocardiogram as a safeguard in pericardiocentesis. J Am Med Assoc. 1956;162(4):264–5.
[196] Tsang TS, Freeman WK, Sinak LJ, et al. Echocardiographically guided pericardiocentesis: evolution and state-of-the-art technique. Mayo Clin Proc. 1998;73(7):647–52.
[197] Callahan JA, Seward JB, Tajik AJ, et al. Pericardiocentesis assisted by two-dimensional echocardiography. J Thorac Cardiovasc Surg. 1983;85(6):877–9.
[198] Loukas M, Walters A, Boon JM, et al. Pericardiocentesis: a clinical anatomy review. Clin Anat. 2012;25(7):872–81.
[199] Stolz LA, Stolz U, Howe C, et al. Ultrasound-guided peripheral venous access: a meta-analysis and systematic review. J Vasc Access. 2015;16(4):321–6.
[200] Egan G, Healy D, O'Neill H, et al. Ultrasound guidance for difficult peripheral venous access: systematic review and meta-analysis. Emerg Med J. 2013;30(7):521–6.
[201] Saugel B, Scheeren TWL, Teboul JL. Ultrasound-guided central venous catheter placement: a structured review and recommendations for clinical practice. Crit Care. 2017;21(1):225.
[202] Gottlieb M, Alerhand S. Ultrasound should be considered for all arthrocentesis. Ann Emerg Med. 2020;75(2):261–2.
[203] Gottlieb M, Avila J, Chottiner M, et al. Point-of-care ultrasonography for the diagnosis of skin and soft tissue abscesses: a systematic review and meta-analysis. Ann Emerg Med. 2020;76(1):67–77.
[204] Ainsworth CD, Salehian O. Echo-guided pericardiocentesis: let the bubbles show the way. Circulation. 2011;123(4):e210–1.
[205] Chiang HT, Lin M. Pericardiocentesis guided by two-dimensional contrast echocardiography. Echocardiography. 1993;10(5):465–9.
[206] Spodick DH. Macrophysiology, microphysiology, and anatomy of the pericardium: a synopsis. Am Heart J. 1992;124(4):1046–51.
[207] Spodick DH, Worcester. Bloody pericardial effusion: clinically significant without intrinsic diagnostic specificity. Chest. 1999;116(6):1506–7.
[208] Pradhan R, Okabe T, Yoshida K, et al. Patient characteristics and predictors of mortality associated with pericardial decompression syndrome: a comprehensive analysis of published cases. Eur Heart J Acute Cardiovasc Care. 2015;4(2):113–20.
[209] Imazio M. Pericardial decompression syndrome: a rare but potentially fatal complication of pericardial drainage to be recognized and prevented. Eur Heart J Acute Cardiovasc Care. 2015;4(2):121–3.
[210] Angouras DC, Dosios T. Pericardial decompression syndrome: a term for a well-defined but rather underreported complication of pericardial drainage. Ann Thorac Surg. 2010;89(5):1702–3. author reply 1703.
[211] Karamichalis JM, Gursky A, Valaulikar G, et al. Acute pulmonary edema after pericardial drainage for cardiac tamponade. Ann Thorac Surg. 2009;88(2):675–7.
[212] Ligero C, Leta R, Bayes-Genis A. Transient biventricular dysfunction following pericardiocentesis. Eur J Heart Fail. 2006;8(1):102–4.
[213] Hemnes AR, Gaine SP, Wiener CM. Poor outcomes associated with drainage of pericardial effusions in patients with pulmonary arterial hypertension. South Med J. 2008;101(5):490–4.
[214] Kopecky SL, Callahan JA, Tajik AJ, et al. Percutaneous pericardial catheter drainage: report of 42 consecutive cases. Am J Cardiol. 1986;58(7):633–5.
[215] Rafique AM, Patel N, Biner S, et al. Frequency of recurrence of pericardial tamponade in patients with extended versus nonextended pericardial catheter drainage. Am J Cardiol. 2011;108(12):1820–5.
[216] Buchanan CL, Sullivan VV, Lampman R, et al. Pericardiocentesis with extended catheter drainage: an effective therapy. Ann Thorac Surg. 2003;76(3):817–20.

Downloaded for Anonymous User (n/a) at The University of Arizona from ClinicalKey.com by Elsevier on April 10, 2023. For personal use only. No other uses without permission. Copyright ©2023. Elsevier Inc. All rights reserved.