RESUSCITATION 179 (2022) 206–213

Available online at ScienceDirect

Resuscitation

journal homepage: www.elsevier.com/locate/resuscitation

Clinical paper

Point-of-care ultrasound compression of the carotid artery for pulse determination in cardiopulmonary resuscitation

Soo Yeon Kang[a,b], *Ik Joon Jo*[a], *Guntak Lee*[a], *Jong Eun Park*[a], *Taerim Kim*[a], *Se Uk Lee*[a], *Sung Yeon Hwang*[a], *Tae Gun Shin*[a], *Kyunga Kim*[c,d,e], *Ji Sun Shim*[c], *Hee Yoon*[a,*]

Abstract

Aim: To identify whether a novel pulse check technique, carotid artery compression using an ultrasound probe, can reduce pulse check times compared to manual palpation (MP).

Methods: This prospective study was conducted in an emergency department between February and December 2021. A physician applied point-of-care ultrasound–carotid artery compression (POCUS-CAC) and assessed the carotid artery compressibility and pulsatility by probe compression during rhythm check time. Another clinician performed MP of the femoral artery. The primary outcome was the difference in the average time for pulse assessment between POCUS-CAC and MP. The secondary outcomes included the time difference in each pulse check between methods, the proportion of times greater than 5 s and 10 s, and the prediction of return of spontaneous circulation (ROSC) during ongoing chest compression.

Results: 25 cardiac arrest patients and 155 pulse checks were analyzed. The median (interquartile range) average time to carotid pulse identification per patient using POCUS-CAC was 1.62 (1.14–2.14) s compared to 3.50 (2.99–4.99) s with MP. In all 155 pulse checks, the POCUS-CAC time to determine ROSC was significantly shortened to 0.44 times the MP time ($P < 0.001$). The POCUS-CAC approach never exceeded 10 s, and the number of patients who required more than 5 s was significantly lower (5 *vs.* 37, $P < 0.001$). Under continuous chest compression, six pulse checks predicted the ROSC.

Conclusions: We found that emergency physicians could quickly determine pulses by applying simple POCUS compression of the carotid artery in cardiac arrest patients.

Keywords: CPR, Point-of-care ultrasound, POCUS, Carotid artery, Pulse check, Palpation

Introduction

Accurate pulse checks by healthcare providers during cardiopulmonary resuscitation (CPR) are crucial for the appropriate management of arrest patients. To minimize interruptions in chest compression, it is vital to check a patient's pulse as rapidly as possible.[1,2] However, several studies have shown that manual palpation of the central arterial pulse is not reliable[3–5] and frequently exceeds the recommended 10 s window.[6–8] Therefore, while the Advanced Cardiac Life Support (ACLS) guidelines by the American Heart Association (AHA) eliminated the pulse check process in 2015,[9] manual pulse palpation remains the standard pulse check method used by healthcare providers during CPR.

Point-of-care ultrasound (POCUS) is increasingly used to help manage cardiac arrest patients.[10] In addition to identifying the reversible cause of cardiac arrest, POCUS is used to determine visible cardiac activity and predict short-term survival.[11–14] However, there were concerns that cardiac ultrasound was associated with longer interruptions in chest compressions[15] and that it had only moderate agreement when determining cardiac activity.[16] Recently, some studies have attempted to determine the return of spontaneous circu-

* Corresponding author at: Department of Emergency Medicine, Samsung Medical Center, Sungkyunkwan University School of Medicine, 115 Irwon-ro, Gangnam-gu, Seoul 06351, Republic of Korea.
E-mail address: wildhi.yoon@samsung.com (H. Yoon).

https://doi.org/10.1016/j.resuscitation.2022.06.025
Received 9 May 2022; Received in Revised form 20 June 2022; Accepted 27 June 2022

0300-9572/© 2022 Elsevier B.V. All rights reserved.

lation (ROSC) by detecting blood flow using carotid artery ultrasound.[17–19] Carotid ultrasound is relatively easy to perform during CPR without interfering with chest compression. It also demonstrated a high inter-observer reliability (α = 0.874) and more than 90% sensitivity and specificity in detecting the presence or absence of a pulse.[18,20]

In a recent case study, a novel pulse-check technique was presented to check the compressibility and pulsatility of the carotid artery using ultrasound probe compression.[17] This approach can assess the pulse quickly and clearly in cases where palpation is either indeterminate or incorrect. This technique was also attempted in a case report,[21] and ROSC was predicted by confirming the change in which the carotid artery did not collapse, despite probe compression under ongoing chest compression. However, these are all preliminary proof-of-concept case studies. Therefore, this study aimed to identify the utility of the carotid artery pulse check technique using POCUS compression by determining whether it can reduce the time required to evaluate ROSC compared to manual palpation.

Materials and methods

Study design and setting

This single-center prospective study was conducted in the emergency department (ED) of a tertiary academic medical center with an annual volume of 70,000 patients in South Korea from February 2021 to December 2021. This study was approved by the Samsung Medical Center Institutional Review Board as a consent waiver (IRB file number 2020–11-116–002) and registered at ClinicalTrial.gov (ID NCT04793386).

Study population

The inclusion criteria were patients aged 18 years or older with out-of-hospital cardiac arrest (OHCA) or in-hospital cardiac arrest (IHCA) who underwent CPR in the ED. The exclusion criteria included difficulty applying ultrasound due to head and neck trauma, anatomical deformity caused by previous neck surgery or mass, and failure to undergo ultrasound due to early cessation of CPR or other reasons.

Study protocol

In accordance with the ACLS guidelines, high-quality CPR was started immediately in patients with cardiac arrest, and carotid ultrasound was conducted as fast as possible. A physician applied point-of-care ultrasound–carotid artery compression (POCUS-CAC) and assessed the carotid artery compressibility and pulsatility by probe compression every 2 min based only on ultrasound findings. Another physician who was blinded to the ultrasound results performed manual palpation (MP) of the femoral artery every 2 min and decided whether the patient had ROSC by referring to their electrocardiogram (ECG) rhythm. They placed their fingers and an ultrasound probe on the patient's skin prior to the rhythm evaluation and then measured the pulse judgement time using a stopwatch during rhythm check time. To evaluate the intra-CPR ROSC prediction, POCUS-CAC was additionally applied during chest compression every 30 s, and the compressibility of carotid artery was assessed (Fig. 1).

Pocus-CAC

The protocol for POCUS-CAC was established based on previous studies.[17,22] A linear transducer was placed in a transverse orientation to the patient's middle neck to identify the carotid artery and internal jugular vein on the screen (Fig. 2A). Subsequently, probe pressure was applied until the internal jugular vein was completely compressed. An absent pulse was defined as a lack of pulsation and complete compression of the carotid artery under probe pressure (Fig. 2B, Video 1). Present pulse was defined as any visual pulsation or incomplete compression of the carotid artery (Fig. 2C, Video 2). The emergency physicians were provided an hour lecture and hands-on demonstration on how to assess a carotid pulse with 2D ultrasound and how to interpret the compressibility and pulsatility of the carotid artery. The Doppler ultrasound settings were not used. The investigators used the predesignated vascular presets of a Samsung Ultrasound HM70A with a 7–16 MHz linear transducer (Samsung Healthcare, Seoul, Korea).

Data collection

The data collected from the enrolled patients included age, sex, body mass index, and medical history. In addition, CPR-related information was collected: arrest location, presence of bystander CPR, no/low flow time, CPR time in the ED, ECG rhythm, arrest cause, result of CPR. The time and results for determining ROSC using the POCUS-CAC and MP methods were collected. If arterial lines were placed, blood pressure data were recorded every 2 min. The ECG rhythms were collected every 2 min.

Outcomes

The primary outcome was the difference in the average time for pulse assessment between POCUS-CAC and MP in each arrest patient. The secondary outcome was the time difference in all pulse assessments between POCUS-CAC and MP. In addition, the pulse check time difference between the two methods according to the ECG rhythm, proportion of times greater than 5 s and 10 s, and factors affecting the pulse check time were evaluated. Intra-CPR ROSC predictions were also evaluated.

Sample size and statistical analysis.

Pulse assessments were performed every 2 min for each patient, and several measurements were obtained; thus, the average value of the time to assess a pulse was used in the analysis. In a previous study, the mean and standard deviation (SD) of the time to detect a pulse by MP was 11.5 s and 8.8 s.[23] We expected the time to assess a pulse using carotid ultrasound to be shortened by at least 5 s. Time values were log-transformed prior to analysis, as the times for checking a pulse were skewed. The primary hypothesis was analyzed using a paired *t*-test. Nineteen participants were required to obtain a statistical power of 80% and a two-sided type I error rate of 5%. We set the sample size to 23 participants, assuming a dropout rate of 20%. Sample size calculation was performed using Performance Analysis of Systems and Software (PASS) 2020 (v20.0.2).

The average time between methods was analyzed using a paired *t*-test. The time difference for each cycle between the methods was analyzed using a generalized estimating equation model. Analyses of ECG-specific time differences between methods were also performed using a generalized estimating equation model. McNemer's test was used to compare the proportion of times greater than 5 and 10 s between the two methods. The factors affecting the time taken to assess a pulse using each method were analyzed using linear regression. Statistical significance was set at $P < 0.05$. Statistical analysis was performed using SAS version 9.4 (SAS Institute, Cary, NC).

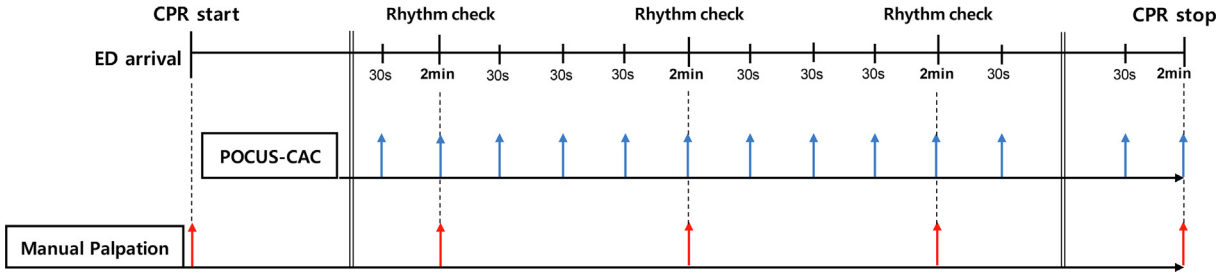

Fig. 1 – Study protocol. Abbreviations. CPR, cardiopulmonary resuscitation; ED, emergency department; POCUS-CAC, point-of-care ultrasound–carotid artery compression.

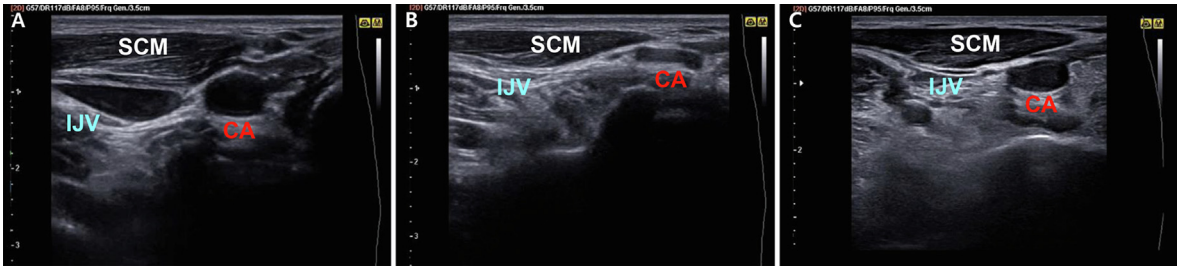

Fig. 2 – ROSC judgement image with POCUS-CAC applied in a cardiac arrest patient. A: before applying POCUS-CAC, B: POCUS-CAC application during cardiac arrest, C: POCUS-CAC application with ROSC. Abbreviations. ROSC, return of spontaneous circulation; POCUS-CAC, point-of-care ultrasound–carotid artery compression; SCM, sternocleidomastoid muscle; IJV, internal jugular vein; CA, carotid artery.

Results

Characteristics of the study participants

Between February 2021 and December 2021, the study involved 25 patients and 20 physicians, with 16 performing manual palpation and 4 conducting carotid ultrasound. We excluded patients aged < 18 years (n = 2), those who had neck trauma (n = 11) or anatomical deformities (n = 2), and those who could not undergo ultrasound due to early cessation of CPR (n = 49), manpower shortage (n = 35), infection risk (n = 7), or delay of ultrasound preparation (n = 8) (Fig. 3). The median age of the patients was 72 years, and 68% (n = 17) were male. A total of 84% (n = 21) of the patients were OHCA patients. In terms of initial ECG rhythms in the ED, asystole was the most common (68%, n = 17), followed by pulseless electrical activity (PEA; 24%) and ventricular fibrillation (V-fib; 8%). The mean (SD) total CPR time in the ED was 21 (8.2) min, and the mean (SD) POCUS-CAC application time was 13 (7.3) min. Ten patients had ROSC after CPR, and only one patient was discharged alive. Under continuous chest compression, six pulse checks predicted intra-CPR ROSC. None of the residents performed carotid ultrasound (Table 1).

Time difference for pulse assessment with POCUS-CAC and MP

The median (interquartile range [IQR]) of the average time for carotid pulse identification per patient using POCUS-CAC was 1.62 (1.14–2.14) s compared to 3.50 (2.99–4.99) s with MP. The average POCUS-CAC time for ROSC judgment was significantly reduced to 0.44 times the average MP time (P < 0.001). There were 155 pulse checks taken from 25 cardiac arrest patients, and the POCUS-CAC time of each cycle was also significantly shorter, less than half the MP time (P < 0.001). In all 155 pulse checks, the time to complete a pulse check with POCUS-CAC never exceeded 10 s, whereas five cases with MP exceeded this. The proportion of patients in whom it took > 5 s to identify their pulse was significantly lower when using the POCUS-CAC method (P < 0.001) (Table 2, Supplementary Fig. 1).

Time difference according to ECG rhythms

POCUS-CAC times were significantly shorter than MP times for all rhythms except V-fib, which was not analyzed due to it being observed infrequently. The difference between the methods was greatest for the PEA rhythm, with POCUS-CAC being 0.38 times that of MP (estimate = -0.966, P < 0.001) (Table 3).

Factors affecting POCUS-CAC or MP times

We assessed whether demographic factors such as age, sex, and previous experience with carotid ultrasound had an impact on pulse detection times. None of the factors, including previous carotid ultrasound experience, affected the time taken to assess a pulse by POCUS-CAC. In contrast, the pulse identification time by MP was significantly shortened by 0.82 times as the physician's grade increased (P = 0.018, Supplementary Table 1).

Discussion

This study evaluated the usefulness of a novel method for pulse check, carotid artery compression using an ultrasound probe, by comparing with manual palpation. The time for ROSC judgement by POCUS-CAC was less than half that of MP, and there were no

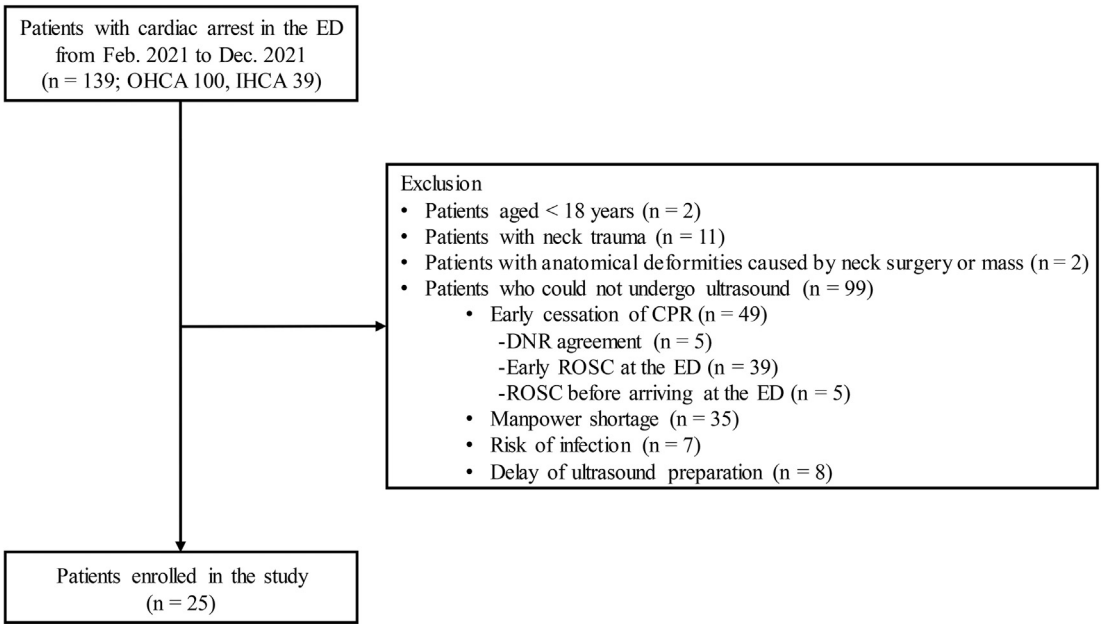

Fig. 3 – Study population. Abbreviations. ED, emergency department; OHCA, out-of-hospital cardiac arrest; IHCA, in-hospital cardiac arrest; CPR, cardiopulmonary resuscitation; DNR, do not resuscitate; ROSC, return of spontaneous circulation.

cases that exceeded 10 s. Ultrasound is called the "stethoscope of the twenty-first century" as it is widely used for the diagnosis and treatment of patients by visualizing what was evaluated via auscultation and palpation.[24] Likewise, by visually observing the collapsed carotid artery under pressure using an ultrasound probe, the POCUS-CAC method significantly shortened the pulse judgement time. This study is noteworthy in that it evaluated the pulse assessment time and feasibility of applying carotid ultrasound in real cardiac arrest patients but not in healthy volunteers[6,8,22] or simulated environments.[3,4,18,19]

Several biomechanical studies have shown that the artery wall is not compressed under physiological pressure.[25–27] When using an ultrasound probe to compress the carotid vessels in a patient with a pulse, the internal jugular vein is entirely compressed because of its low pressure; meanwhile, the carotid artery is not flattened, and the structure of the blood vessel is preserved. In cardiac arrest situations, only 20–40% of normal cardiac output is produced, even if chest compressions are appropriately delivered.[28,29] Therefore, this study was conducted assuming that the carotid artery would be compressed in the same way as the jugular vein collapses when an ultrasound probe is applied during CPR. Using the POCUS-CAC approach, it was possible to judge ROSC directly and quickly while pressing the probe, with judgement taking less than 2 s on average.

Six pulse checks were determined to be ROSC as pulsatile carotid arteries were observed despite collapse following probe compression (Video 3). Carotid artery collapse may be observed in severe hypovolemia or under excessive probe force in a weak pulse condition. In addition, in a low blood pressure state, detection of the pulsatile carotid artery is challenging (Video 4). Stephen *et al.* demonstrated that blood pressure was the only significant predictor of accuracy when detecting a pulse using carotid ultrasound; in addition, the sensitivity was reduced with lower blood pressure.[18] Thus, we used POCUS-CAC to assess both compressibility and pulsatility, and we were able to discern the non-compressible pulsing features of the carotid artery against the pressing force of the ultrasound probe more clearly, even in situations with low blood pressure (Video 5).

Many previous studies have demonstrated that manual palpation is inaccurate and requires a prolonged time.[7] The average pulse checks by MP took a median of 3.5 s, which was considerably short compared to in other studies that reported median values of 9.29 to 11.5 s.[23,30] This could be because 84% of MPs were conducted by physicians that were third-year residents or higher; notably, pulse identification times decreased with physician grade (Supplementary Table 1). Furthermore, pulse checks may have been faster because the MP physicians were not blinded to the ECG rhythms. Nevertheless, there were five pulse checks where MP could not detect pulses during the initial 10 s. Carotid ultrasound, on the other hand, could confirm pulsatile, non-compressible carotid arteries at 1.10, 2.12, 2.24, 3.19, and 5.41 s. Pulses were finally identified in these cases after prolonged palpations exceeding 10 s, and the mean arterial pressure was 23–63 mmHg. Similarly, one study identified that MP failed to identify pulses in patients with ROSC who had a low systolic blood pressure values below 60 mmHg,[31] suggesting that ultrasound may be more beneficial for pulse checks in this situation.

Eight patients (32%) underwent arterial line placement before and during CPR. In the six pulse checks, the pulsatile arteries were first observed on POCUS-CAC, and then the pulses were checked with MP at the femoral site. Finally, the radial arterial waveform and blood pressure data were shown on the monitor, and the mean arterial pressure at that time was 23–44 mm Hg. In this investigation, POCUS-CAC and MP were performed at different locations because the pulse could not be checked while compressing both carotid arteries. Although there may be slight differences in intensity or time depending on the location of the pulse check, ROSC was determined most rapidly using POCUS-CAC in this study. Arterial pressure monitoring is recommended in the AHA guidelines in combination with CPR as it may be used to detect ROSC.[1] However, it is not easy

Table 1 – Baseline characteristics of the study participants.

Characteristics	Patients ($n = 25$)	Characteristics	Patients ($n = 25$)
Age (year)	73 (58–86)	Arterial line placement	8 (32)
Sex (male)	17 (68)	POCUS-CAC	
BMI (kg/m^2)	23.1 (3.15)	Scan initiation time (min)	9 (7.2)
Past medical history		Total application time (min)	13 (7.3)
HTN	8 (32)	Physician ($n = 4$)	
DM	7 (28)	Fellow	11 (44)
Dyslipidemia	2 (8)	Staff	14 (56)
Chronic heart disease	8 (32)	Experience with carotid US (cases)	
Chronic lung disease	4 (16)	0∼1	2 (8)
Chronic liver disease	1 (4)	2∼5	4 (16)
Chronic renal disease	2 (8)	6∼10	5 (20)
Cerebral vascular accident	3 (12)	> 10	14 (56)
Malignancy	6 (24)	Manual palpation physician ($n = 16$)	
Location of cardiac arrest		Residents 1/2	1 (4)/3 (12)
OHCA	21 (84)	Residents 3/4	10 (40)/6 (24)
Home	11 (44)	Fellow	3 (12)
Work	1 (4)	Staff	2 (8)
Street	5 (20)	Cause of arrest	
Others	4 (16)	MI/arrhythmia/cardiogenic	3 (12)/1 (4)/2 (8)
IHCA	4 (16)	Hypoxia	7 (28)
Witnessed arrest	14 (56)	Metabolic/sepsis	1 (4)/5 (20)
Bystander CPR	19 (76)	Trauma/brain hemorrhage	4 (16)/1 (4)
Mechanical CPR	22 (88)	Unknown	1 (4)
Pre-ECG rhythm		Reason for stopping CPR	
Unknown	6 (24)	ROSC	10 (40)
Asystole	14 (56)	DNR	1 (4)
PEA	3 (12)	No possibility of resuscitation	14 (56)
V-fib	2 (8)	ECMO	0 (0)
Initial ED ECG rhythm		Prognosis after CPR	
Asystole	17 (68)	No ROSC	15 (60)
PEA	6 (24)	ROSC	10 (40)
V-fib	2 (8)	Death within 24 hours	8 (32)
No flow time (min)	4 (0–15)	Death after 24 hours	1 (4)
Low flow time (min)	32 (13.7)	Survival discharge	1 (4)
Total ED CPR time (min)	21 (8.2)	COVID-19 (positive)	2 (8)

Data were reported as numbers (percentage, %), mean (standard deviation, SD), or median (interquartile range, IQR).

Abbreviations BMI, body mass index HTN, hypertension DM, diabetes mellitus OHCA, out-of-hospital cardiac arrest IHCA, in-of-hospital cardiac arrest CPR, cardiopulmonary resuscitation ECG, electrocardiogram PEA, pulseless electrical activity V-fib, ventricular fibrillation ED, emergency department POCUS-CAC, point-of-care ultrasound–carotid artery compression US, ultrasound MI, myocardial infarction ROSC, return of spontaneous circulation DNR, do not resuscitate ECMO, extracorporeal membrane oxygenation COVID-19, coronavirus disease 2019.

Table 2 – Differences in time for pulse assessment with POCUS-CAC and MP.

	POCUS-CAC	MP	Time Difference = log (POCUS-CAC) minus log (MP)			
Average time per patient	1.62 s	3.50 s	Mean	SD	SE	P-value
($n = 25$)	(1.14–2.14 s)	(2.99–4.99 s)	−0.830	0.385	0.077	< 0.001
All pulse check	1.31 s	3.00 s	Estimate	95% CL	SE	P-value
($n = 155$)	(1.00–2.12 s)	(2.19–4.91 s)	−0.828	−0.9613 ∼ -0.6946	0.068	< 0.001
Case > 5 s, n (%)	5 (3)	37 (24)	P-value < 0.001			
Case > 10 s, n (%)	0	5 (3)	-			

The actual time taken to determine ROSC is presented as the median (IQR). Time data for the difference analysis were log-transformed to follow a normal distribution. The average times per patient between methods were analyzed using a paired *t*-test, and all times for each pulse-check cycle were analyzed using a generalized estimating equation model. The proportions of times greater than 5 and 10 s between the two methods were analyzed using McNemer's test.

Abbreviations. POCUS-CAC, point-of-care ultrasound–carotid artery compression; MP, manual palpation; log, logarithm; SD, standard deviation; SE, standard error; CL, confidence limits; IQR, interquartile range.

Table 3 – Time difference according to ECG rhythms between two methods.

ECG rhythm	*N*	Estimate (95% CL)	SE	P-value
Asystole	100	−0.764 (−0.945 to −0.584)	0.092	< 0.001
PEA	32	−0.966 (−1.069 to −0.863)	0.053	< 0.001
V-fib	3	−1.090 (−1.090 to −1.090)	0	NA
Pulseless VT	6	−0.898 (−1.071 to −0.725)	0.088	< 0.001
ROSC rhythm	14	−0.849 (−1.281 to −0.417)	0.221	0.001

All time data were log-transformed and analyzed using a generalized estimating equation model. Differences in log (POCUS-CAC time) minus log (MP time) are expressed as estimates (95% CL).

Abbreviations. ECG, electrocardiogram; CL, confidence limits; SE, standard error; PEA, pulseless electrical activity; V-fib, ventricular fibrillation; NA, not applicable; VT, ventricular tachycardia; ROSC, return of spontaneous circulation.

to implant arterial lines in cardiac arrest patients, and we detected a time gap in the displayed pressure through the arterial line after ROSC.

In our study, six pulse checks out of 10 ROSC cases predicted ROSC in intra-CPR circumstances. During ongoing chest compression, collapse of the carotid artery caused by probe compression was no longer observed; meanwhile, the vein still collapsed, and ROSC was confirmed at the next pulse check time (Video 6, 7). The presence or absence of pulse was used to determine an appropriate resuscitation algorithm for cardiac arrest. If ROSC can be identified during chest compressions, then the next step can be determined more rapidly. However, as no outcome-related study has been conducted using this method, it is questionable whether non-compressible artery during chest compression can be the basis for immediately stopping chest compression. In addition, assessing compressibility under chest compression is challenging because of the motion created by chest compression. Therefore, validation and outcome-related studies on POCUS-CAC in various settings should be conducted.

Previous studies showed that brief carotid ultrasound education consisting of hands-on practice or self-directed learning through video clips is sufficient to identify the central pulse quickly and reliably.[20,22] In our study, participants with less than 10 carotid ultrasound experiences performed 44% of cases after only an hour-long online lecture with demonstrations; they could promptly assess ROSC using the POCUS-CAC without difficulty. However, in the hands of an inexperienced sonographer, longer compression times may result in decreased cerebral blood flow; therefore, it is essential to avoid this when compressing the carotid artery.

Although carotid ultrasound does not provide clues regarding arrest causes and cannot substitute the role of cardiac POCUS in arrest patient care, it may help significantly reduce the pulse identification time. In addition, it is expected to be applicable in the prehospital stages by using portable ultrasound following short training sessions. Furthermore, if pulse checks using POCUS-CAC are performed along with chest compression noise correction ECG, it is anticipated that the prognosis of cardiac arrest patients would be greatly improved by performing CPR without stopping chest compressions.

Our study had some limitations. First, this study had a limited sample size and was performed at a single institution; it may not account for the variability in difficulty levels of pulse detection in the population. Additionally, physicians with varying grades or ultrasound experiences were not included in the study. Therefore, these findings cannot be extrapolated to other settings. Second, there was convenience sampling due to the restriction of the number of medical staff participating in CPR to prevent coronavirus disease 2019 transmission. Furthermore, carotid ultrasound could not be performed in some cases owing to delayed preparation of ultrasound equipment. Therefore, selection bias may have occurred. Third, there was no gold standard for pulse detection to confirm or deny the ultrasound findings. Only eight patients had an arterial line, and arterial pressure data appeared late under low blood pressure conditions. Thus, this study was not able to evaluate the accuracy of ROSC judgement between the methods. Fourth, the MP physicians were not blinded to the ECG rhythms; therefore, MP times were not measured via pure manual sensations. Fifth, image quality and inter-rater reliability could not be assessed because the pulse evaluation images were not saved. Sixth, there was no consideration of pathologic changes in the carotid arterial wall, such as atherosclerosis. Finally, it was difficult to generalize the probe locations and compression intensities.

Conclusions

We found that emergency physicians could quickly determine pulses by applying simple POCUS compression of the carotid artery in patients with cardiac arrest. Large-scale prospective studies are needed to determine whether patient outcomes can be improved by using this method.

Conflict of interest

No potential conflict of interest relevant to this article was reported.

Funding

This research received no external funding.

CRediT authorship contribution statement

Soo Yeon Kang: Methodology, Data curation, Writing – original draft, Writing – review & editing. **Ik Joon Jo:** Methodology, Writing – review & editing. **Guntak Lee:** Data curation, Writing – review & editing. **Jong Eun Park:** Writing – review & editing. **Taerim Kim:** Writing – review & editing. **Se Uk Lee:** Writing – review & editing. **Sung Yeon Hwang:** Writing – review & editing. **Tae Gun Shin:** Writing – review & editing. **Kyunga Kim:** Formal analysis. **Ji Sun Shim:** Formal analysis. **Hee Yoon:** Conceptualization, Methodology, Data

curation, Writing – original draft, Writing – review & editing, Supervision.

Acknowledgements

None.

Institutional Review Board Statement

This study was approved by the Institutional Review Board of Samsung Medical Center (IRB file number 2020-11-116-002).

Informed Consent Statement

This study was exempted from consent through the Institutional Review Board.

Data Availability Statement

Data related to this study cannot be released due to the information security policies of the hospitals.

Appendix A. Supplementary data

Supplementary data to this article can be found online at https://doi.org/10.1016/j.resuscitation.2022.06.025.

Author details

[a]*Department of Emergency Medicine, Samsung Medical Center, Sungkyunkwan University School of Medicine, Seoul 06351, Republic of Korea* [b]*Department of Emergency Medicine, College of Medicine, Kangwon National University, Chuncheon 24341, Gangwon-do, Republic of Korea* [c]*Biomedical Statistics Center, Research Institute for Future Medicine, Samsung Medical Center, Seoul 06351, Republic of Korea* [d]*Department of Digital Health, SAIHST, Sungkyunkwan University, Seoul 06351, Republic of Korea* [e]*Department of Data Convergence & Future Medicine, Sungkyunkwan University School of Medicine, Seoul 06351, Republic of Korea*

REFERENCES

1. Panchal AR, Bartos JA, Cabanas JG, et al. Part 3: Adult Basic and Advanced Life Support: 2020 American Heart Association Guidelines for Cardiopulmonary Resuscitation and Emergency Cardiovascular Care. Circulation 2020;142:S366–468.
2. Soar J, Bottiger BW, Carli P, et al. European Resuscitation Council Guidelines 2021: Adult advanced life support. Resuscitation 2021;161:115–51.
3. Lapostolle F, Le Toumelin P, Agostinucci J, Catineau J, Adnet F. Basic Cardiac Life Support Providers Checking the Carotid Pulse: Performance, Degree of Conviction, and Influencing Factors. Acad Emerg Med 2004;11:878–80.
4. Liberman M, Lavoie A, Mulder D, Sampalis J. Cardiopulmonary resuscitation: errors made by pre-hospital emergency medical personnel. Resuscitation 1999;42:47–55.
5. Tibballs J, Russell P. Reliability of pulse palpation by healthcare personnel to diagnose paediatric cardiac arrest. Resuscitation 2009;80:61–4.
6. Bahr J, Klingler H, Panzer W, Rode H, Kettler D. Skills of lay people in checking the carotid pulse. Resuscitation 1997;35:23–6.
7. Dick W, Eberle B, Wisser G, Schneider T. The carotid pulse check revisited: What if there is no pulse? Crit Care Med 2000;28:N183–5.
8. Ochoa J, Ramalle-Gomara E, Carpintero JM, Garcıa A, Saralegui I. Competence of health professionals to check the carotid pulse. Resuscitation 1998;37:173–5.
9. Cummins R, Hazinski M. Guidelines based on fear of type II (false-negative) errors : why we dropped the pulse check for lay rescuers. Circulation 2000;102:I377–9.
10. Blanco P, Martinez BC. Point-of-care ultrasound in cardiopulmonary resuscitation: a concise review. J Ultrasound 2017;20:193–8.
11. Blyth L, Atkinson P, Gadd K, Lang E. Bedside focused echocardiography as predictor of survival in cardiac arrest patients: a systematic review. Acad Emerg Med 2012;19:1119–26.
12. Chardoli M, Heidari F, Rabiee H, Sharif-Alhoseini M, Shokoohi H, Rahimi-Movaghar V. Echocardiography integrated ACLS protocol versus conventional cardiopulmonary resuscitation in patients with pulseless electrical activity cardiac arrest. Chin J Traumatol 2012;15:284–7.
13. Flato UA, Paiva EF, Carballo MT, Buehler AM, Marco R, Timerman A. Echocardiography for prognostication during the resuscitation of intensive care unit patients with non-shockable rhythm cardiac arrest. Resuscitation 2015;92:1–5.
14. Gaspari R, Weekes A, Adhikari S, et al. Emergency department point-of-care ultrasound in out-of-hospital and in-ED cardiac arrest. Resuscitation 2016;109:33–9.
15. Clattenburg EJ, Wroe P, Brown S, et al. Point-of-care ultrasound use in patients with cardiac arrest is associated prolonged cardiopulmonary resuscitation pauses: A prospective cohort study. Resuscitation 2018;122:65–8.
16. Hu K, Gupta N, Teran F, Saul T, Nelson BP, Andrus P. Variability in Interpretation of Cardiac Standstill Among Physician Sonographers. Ann Emerg Med 2018;71:193–8.
17. Simard RD, Unger AG, Betz M, Wu A, Chenkin J. The POCUS Pulse Check: A Case Series on a Novel Method for Determining the Presence of a Pulse Using Point-of-Care Ultrasound. J Emerg Med 2019;56:674–9.
18. Sanchez S, Miller M, Asha S. Assessing the validity of two-dimensional carotid ultrasound to detect the presence and absence of a pulse. Resuscitation 2020;157:67–73.
19. Germanoska B, Coady M, Ng S, Fermanis G, Miller M. The reliability of carotid ultrasound in determining the return of pulsatile flow: A pilot study. Ultrasound 2018;26:118–26.
20. Smith DJ, Simard R, Chenkin J. Checking the pulse in the 21st century: Interobserver reliability of carotid pulse detection by point-of-care ultrasound. Am J Emerg Med 2021;45:280–3.
21. Hansol C, Seok Goo K, IkJoon J, Hee Y. Use of carotid artery compressibility detected on ultrasonography during chest compression to validate return of spontaneous circulation. Clin Case Rep 2020;1:1–4.
22. Badra K, Coutin A, Simard R, Pinto R, Lee JS, Chenkin J. The POCUS pulse check: A randomized controlled crossover study comparing pulse detection by palpation versus by point-of-care ultrasound. Resuscitation 2019;139:17–23.
23. Yamane D, McCarville P, Sullivan N, et al. Minimizing Pulse Check Duration Through Educational Video Review. West J Emerg Med 2020;21:276–83.
24. Gillman LM, Kirkpatrick AW. Portable bedside ultrasound: the visual stethoscope of the 21st century. Scand J Trauma Resusc Emerg Med 2012;20:1–8.
25. Carew T, Vaishnav R, Patel D. Compressibility of the arterial wall. Circ Res 1968;23:61–8.
26. Chuong CJ, Fung YC. Compressibility and constitutive equation of arterial wall in radial compression experiments. J Biomech 1984;17:35–40.
27. Girerd XJ, Acar C, Mourad JJ, Boutouyrie P, Safar ME, Laurent S. Incompressibility of the human arterial wall: an in vitro ultrasound study. J Hypertens Suppl 1992;10:S111–5.

28. Andreka P, Frenneaux MP. Haemodynamics of cardiac arrest and resuscitation. Curr Opin Crit Care 2006;12:198–203.
29. Luce JM, Ross BK, O'Quin RJ, et al. Regional blood flow during cardiopulmonary resuscitation in dogs using simultaneous and nonsimultaneous compression and ventilation. Circulation 1983;67:258–65.
30. Zengin S, Gumusboga H, Sabak M, Eren SH, Altunbas G, Al B. Comparison of manual pulse palpation, cardiac ultrasonography and Doppler ultrasonography to check the pulse in cardiopulmonary arrest patients. Resuscitation 2018;133:59–64.
31. Lee Y, Shin H, Choi HJ, Kim C. Can pulse check by the photoplethysmography sensor on a smart watch replace carotid artery palpation during cardiopulmonary resuscitation in cardiac arrest patients? a prospective observational diagnostic accuracy study. BMJ Open 2019;9 e023627.